
Ultrasound examination of the femoral and popliteal arteries

Sorin Crişan

5th Medical Clinic, „Iuliu Haţieganu” University of Medicine and Pharmacy Cluj-Napoca, Romania

Doppler ultrasonography of the femoral-popliteal segment is preceded by clinical examination and ankle-brachial pressure measurement. This important noninvasive technique provides detailed information on morphology and flow pattern. Doppler ultrasound allows detection of haemodynamically significant lesions in patients with lower extremity artery disease and selection of the appropriate lesions for endovascular procedures. This method is also useful for the routine follow-up after angioplasty, stent implantation, and bypass graft [1,2].

Examination technique

In order to evaluate the femoral arteries, the patient lies supine, with the leg in slight external rotation. Popliteal artery examination is performed with the patient in the supine position with a slight flexion of the knee. If needed, the patient lies prone with the knee in complete extension. In special situations affecting the heart, lungs and articulations, adequate *insonation* of the femoral-popliteal segment can be performed with the patient sitting or standing [3,4].

Linear array transducers, with a combination of 7-12 MHz B-mode with a 5-7.5 MHz pulse Doppler, provide complete arterial visualization.

Examination technique has two steps. The first step, including longitudinal and transverse scans, allows identification and characterization of the arteries of interest using B-mode and color flow imaging. Longitudinal

scan, starting at the groin and continued distally, is mandatory. The marker of the transducer is located cranial so that the image is oriented with the patient's head to the left of the screen. Beginners may choose to start the examination by *cross-sectional* view in order to easily identify the anatomic relationships between arteries and surrounding tissues. The second stage of the examination is represented by flow evaluation using pulsed Doppler ultrasound in longitudinal view with a Doppler angle of 60 degrees or less [3].

Normal anatomy

The femoral artery is the continuation of the external iliac artery at the level of the inguinal ligament. The artery travels the length of the thigh along a line projected from the mid inguinal ligament to the medial condyle of femur. The femoral artery gives off a branch, the deep femoral artery (DFA), in the proximal part of the femoral triangle. This arterial segment is also called “the femoral bifurcation”. The segment of the femoral artery located proximally to the arising of the DFA is called the common femoral artery (CFA). The distal part of the femoral artery is represented by the superficial femoral artery (SFA) (fig 1-4) [3,5].

The CFA lies in front of the hip joint. It has a length of 2-5 cm and a diameter of 8.2 ± 0.14 mm. The femoral vein is located medial to the CFA. The DFA originates from the posterolateral side of the femoral artery then passes to the back of the thigh and ends in the lower third of this segment [3,5].

The SFA runs medial to the body of the femur in the femoral triangle, in the upper third of the thigh, and in the adductor canal, in the middle third of the thigh. The length of the SFA is more than 15-20 cm. The proximal segment has a diameter of 6.0 ± 0.12 mm. The diameter of the distal part of the artery, more profound, is 5.4 ± 0.11

Received Accepted
Med Ultrason

2012, Vol. 14, No 1, 74-77

Corresponding author: Sorin Crişan, MD PhD
Assoc. Prof. of Internal Medicine
5th Medical Clinic
Str. Tăbăcarilor 11, Zip Code 400139
Phone: + 40722550880
Email: crisan.sorin@gmail.com

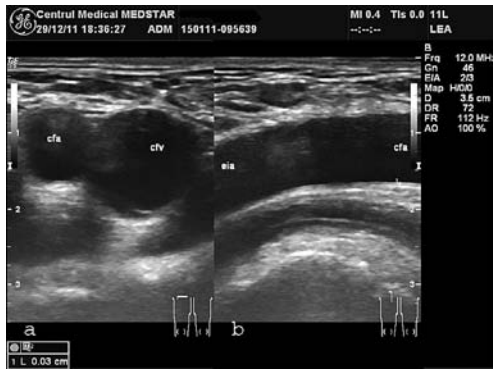


Fig 1. Femoral vessels scan at the level of the right groin. a. transverse view. b. longitudinal view. cfa: common femoral artery. cfv: common femoral vein. eia: external iliac artery.

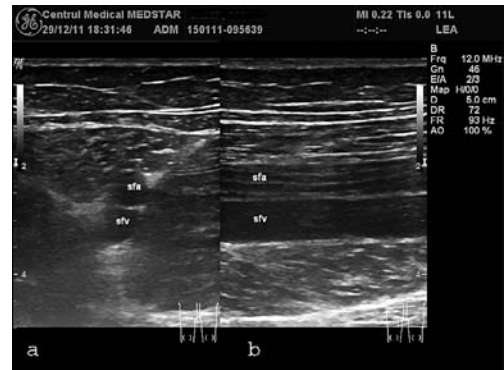


Fig 4. Superficial femoral vessels in the middle third of the thigh. Intraluminal parallel echogenic artifacts. a. short-axis view. b. long-axis view. sfa: superficial femoral artery. sfv: superficial femoral vein.

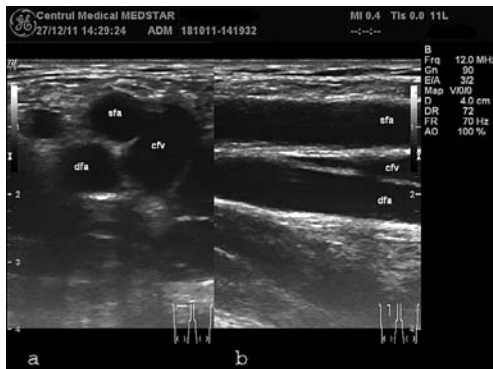


Fig 2. B-mode image of the femoral vessels within the right femoral triangle. a. short-axis view. b. long-axis view. sfa: superficial femoral artery. dfa: deep femoral artery. cfv: common femoral vein.

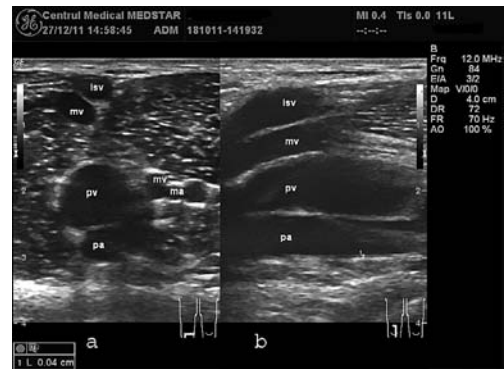


Fig 5. Vessels of the popliteal fossa. a. transverse view. b. longitudinal view. pa: popliteal artery. pv: popliteal vein. ma: muscular artery. mv: muscular vein. lsv: lesser (small) saphenous vein.

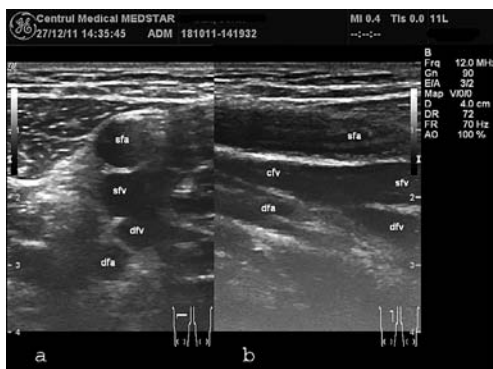

Fig 3. Right femoral triangle. Blood vessels are not perfectly aligned in the same parasagittal plane. a. transverse view. b. longitudinal view. sfa: superficial femoral artery dfa: deep femoral artery. cfv: common femoral vein. sfv: superficial femoral vein. dfv: deep femoral vein.

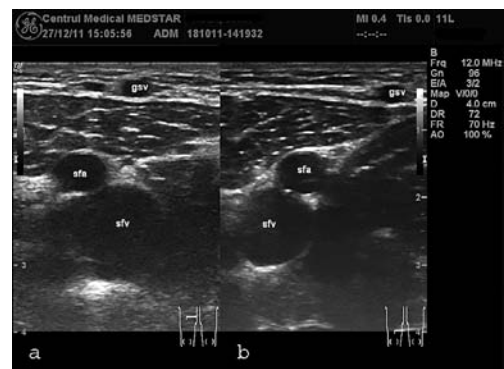


Fig 6. Transverse view showing the spatial relationship between the superficial femoral vessels. a. in the upper third of the thigh. b. in the middle third of the thigh. sfa: superficial femoral artery. sfv: superficial femoral vein. gsv: great saphenous vein.

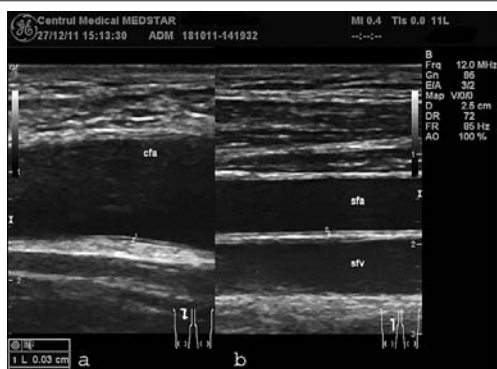

Fig 7. Longitudinal view of the right common and superficial femoral arteries. Normal intima-media thickness. a. common femoral artery. b. superficial femoral artery. cfa: common femoral artery. sfa: superficial femoral artery. sfv: superficial femoral vein.

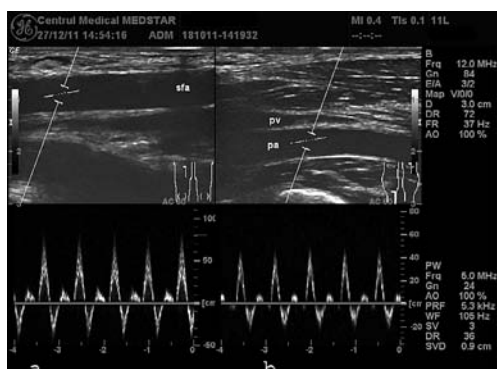


Fig 8. Longitudinal view of the right superficial femoral and popliteal arteries. Typical Doppler spectrum. a. superficial femoral artery. b. popliteal artery. sfa: superficial femoral artery. pa: popliteal artery. pv: popliteal vein.

mm. The femoral vein runs medial to the proximal segment of the SFA, behind the middle part, and lateral or posterolateral to the distal third of the artery (fig 6) [3,5].

The SFA passes through the opening in the Adductor magnus and becomes the popliteal artery (PA) at the junction of the middle with the lower third of the thigh. The PA runs behind the femur and anterior to the *popliteal vein*. Because the examination is performed from the popliteal fossa, the *popliteal vein is located* anterior to the artery (fig 5). The PA divides into anterior and posterior tibial arteries at the level of the lower border of the Popliteus. The length of the PA is more than 6-8 cm. The diameter of the proximal and middle segments is 5.4 ± 0.11 mm. The distal part of the artery has a slightly smaller diameter [3,5].

The CFA and PA diameter is significantly correlated with sex, age, height, weight, and body surface area. The diameter is larger in men than in women [6].

The wall of the femoral-popliteal segment has a *trilaminar structure* representing the intima-media complex. The inner and outer parallel layers of the wall are hyperechoic while the middle zone is hypoechoic. The distance between the two hyperechoic layers is called the intima-media thickness (IMT) and it is measured at the far arterial wall in longitudinal plane (fig 1,5,7). The normal value of the IMT increases with age and it is less than 0.9 mm [3].

Normal flow pattern

The femoral-popliteal segment has a triphasic flow pattern due to the high peripheral resistance. The first component of the Doppler signal corresponds to the rapid antegrade flow during systole. The second part of the spectral waveform contour is represented by the reversal flow during early diastole. The little antegrade flow during mid-diastole produces the third waveform. There is no detectable signal in late diastole (fig 8) [3,4].

Peak systolic velocity is high: 114.1 ± 24.9 cm/sec in the CCA, 93.6 ± 14.1 cm/sec in the SCA, and 68.8 ± 13.5 cm/sec in the PA. Peak diastolic reverse velocity and peak diastolic forward velocity are much lower than the systolic velocity [3].

The width of the spectral band is narrow especially during systole. There is a slightly increased spectral bandwidth at the level of the femoral bifurcation due to normal flow disturbances [3].

Advantages

The most important advantages of the method are the rare arterial variants (location of the DFA origin, duplication of the SFA, high bifurcation of the PA), good interobserver reproducibility, adequate detection of some changes in vessel morphology like increased IMT and plaque as indicators of subclinical atherosclerosis, and accurate information on lesion type, location, extent and severity [1,3,7].

Compared with angiography, Doppler ultrasound detects the haemodynamically significant stenosis (diameter reduction of more than 50%) with a sensitivity of 85-90% and a specificity of more than 95% [1].

Limitations and sources of error

There are several limitations of the method: deep location of the distal SFA in patients with obesity and oedema, low detection of the lumen in the presence of

near wall calcifications, involuntary leg movements, and hyperaesthesia. B-mode and color imaging can not determine the correct degree of arterial narrowing without the help of the pulsed Doppler.

Important sources of error are the insufficient examiner's experience and time, inappropriate use of some parameters (velocity scale, Doppler angle, placement and size of the sample volume, wall filter, gray-scale, color and Doppler gain), and ultrasound artifacts (intraluminal parallel echogenic lines as shown in fig 4, *marginal shadow phenomenon*, and aliasing)

References

1. Tendera M, Aboyans V, Bartelink ML et al. ESC Guidelines on the diagnosis and treatment of peripheral artery diseases. Document covering atherosclerotic disease of extracranial carotid and vertebral, mesenteric, renal, upper and lower extremity arteries. The Task Force on the Diagnosis and Treatment of Peripheral Artery Diseases of the European Society of Cardiology (ESC). Eur Heart J 2011; 32: 2851-2906.
2. Rooke TW, Hirsch AT, Misra S, et al. 2011 ACCF/AHA Focused Update of the Guideline For the Management of Patients With Peripheral Artery Disease (Updating the 2005 Guideline). A Report of the American College of Cardiology Foundation/American Heart Association Task Force on Practice Guidelines. Circulation 2011; 124: 2020-2045.
3. Zierler RE, Zierler BK. Duplex sonography of lower extremity arteries. In: Zwiebel WJ (ed). Introduction to vascular ultrasonography, 4th Edition. Philadelphia, W.B. Saunders Company 2000: 263-283.
4. Gerhard-Herman M, Gardin JM, Jaff M, Mohler E, Roman M, Naqvi TZ. Guidelines for Noninvasive vascular Laboratory Testing: A Report from the American Society of Echocardiography and the Society of Vascular Medicine and Biology. J Am Soc Echocardiogr 2006; 19: 955-972.
5. Gray's Anatomy of the Human Body. Twentieth Edition. New York: Bartleby.com, 2000. VI. The Arteries. 6. The Arteries of the Lower Extremity. a. The Femoral Artery. <http://www.bartleby.com/107/157.html> (website accessed on February 3, 2012)
6. Sandgren T, Sonesson B, Ahlgren R, Länne T. The diameter of the common femoral artery in healthy human: influence of sex, age, and body size. J Vasc Surg 1999; 29: 503-510.
7. Kafetzakis A, Kochiadakis G, Laliotis A, et al. Association of Subclinical Wall Changes of Carotid, Femoral and Popliteal Arteries With Obstructive Coronary Artery Disease in Patients Undergoing Coronary Angiography. Chest 2005; 128: 2538-2543.