

Point shear wave speed measurement in differentiating benign and malignant focal liver lesions

Yi Dong¹, Wen-Ping Wang¹, Yadan Xu², Jiaying Cao¹, Feng Mao¹, Cristoph F Dietrich³

¹Department of Ultrasound, Zhongshan Hospital, Fudan University, Shanghai, China, ²Shanghai Institute of Medical Imaging, Shanghai, China, ³Med. Klinik 2, Caritas-Krankenhaus Bad Mergentheim, Bad Mergentheim, Germany

Abstract

Aim: To investigate the value of ElastPQ measurement for differential diagnosis of benign and malignant focal liver lesions (FLLs) by using histologic results as a reference standard. **Material and methods:** A total of 154 patients were included. ElastPQ measurement was performed for each lesion in which the shear wave speed (SWS) was measured. The difference in SWS and SWS ratio of FLL to surrounding liver were evaluated, and the cut off value was investigated. Receiver operating characteristic (ROC) curve was plotted to evaluate the diagnostic performance. Histology as a gold standard was obtained by surgery in all patients. **Results:** A total of 154 lesions including 129 (83.7 %) malignant FLLs and 25 (16.3 %) benign ones were analysed. The SWS of malignant and benign FLLs was significantly different, 2.77 ± 0.68 m/s and 1.57 ± 0.55 m/s ($p<0.05$). The SWS ratio of each FLL to surrounding liver parenchyma was 2.23 ± 0.49 for malignant and 1.14 ± 0.36 for benign FLLs ($p<0.05$). The cut off value for differential diagnosis was 2.06 m/s for SWS and 1.67 for SWS ratio. **Conclusions:** ElastPQ measurement provides reliable quantitative stiffness information of FLLs and may be helpful in the differential diagnosis between malignant and benign FLLs.

Keywords: ElastPQ; shear wave speed; focal liver lesions; differential diagnosis

Introduction

Accurate and proper diagnosis of focal liver lesions (FLLs) is of vital importance in clinical practice. Up to date, non-invasive imaging techniques with administration of contrast agents, such as computed tomography (CT), contrast enhanced ultrasound (CEUS), and magnetic resonance (MR) imaging have been widely used to evaluate the morphology and vascularization perfusion of FLLs [1]. However, their diagnostic sensitivity and specificity can be affected by the size of FLLs, which may result in false-positive or false-negative results [2]. In addition, those imaging methods are more expensive, not easily accessible and may have a potential risk of allergic reaction or radiation exposure [3].

Recent technical advances in ultrasound shear wave elastography (SWE) increase the diagnostic efficiency of ultrasound and make it possible to evaluate liver fibrosis and cirrhosis [4,5]. Point shear wave elastography (PSWE) as a part of the second generation of ultrasound SWE methods, includes acoustic radiation force impulse (ARFI) and elastography point quantification (ElastPQ). PSWE improves the feasibility and accuracy of stiffness measurements, even in obese patients and patients with ascites [6]. It enjoys high levels of intraobserver and interobserver agreement [6]. PSWE has been reported to be useful in noninvasively diagnosis and characterization of different solid tumors, which have been found to be stiffer than the surrounding tissues: e.g., breast lesions [7], prostate cancer [8], thyroid cancer [9], lymph nodes [10] and pancreatic masses [11]. Beyond CEUS, CT or MRI, it may help discriminating malignant versus benign masses, particularly with regard to patients unsuitable for contrast enhanced imaging [12].

Up till now, only a few studies have focused on the SWE stiffness quantification of FLLs. Most of them used ARFI technology [13-15], some with 2D SWE using Aixplorer (SuperSonic Imagine, France) [16]. Their re-

Received 19.05.2017 Accepted 13.06.2017

Med Ultrason

2017, Vol. 19, No 3, 259-264

Corresponding author: Prof. Wen-Ping Wang

Department of Ultrasound,
Zhongshan Hospital, Fudan University
180 Fenglin Road, Shanghai, 200032, China
Phone: 86 (0)21- 64041990 - 2474
Fax: 86 (0)21 - 64220319
E-mail: puguang61@126.com

sults showed that SWE have a relevant diagnostic role in clinical practice [12,14,17-19].

However, only a few data are available so far for ElastPQ technology in evaluation of FLLs [20-23]. Our prospective study aims to evaluate the feasibility of ElastPQ techniques in the differential diagnosis and characterization of histologically proved FLLs.

Material and methods

Institutional board approval

This prospective study was approved by our institutional review board. All patients gave their full informed consent before liver SWE examination. The procedure followed was in accordance with the Declaration of Helsinki.

Patients

Between July 2015 and June 2016, 154 consecutive patients (46 women and 108 men; age range: 15–91 years, mean: 55.5 years \pm 10.3) who were referred to our institution for FLLs SWE assessment were included. The final diagnoses were based on histopathologic results obtained from liver surgery (Table I).

The inclusion criteria were as follows: presence of a solid FLL; plan to accept surgery and histopathological analysis; absence of any previous local treatments (i.e. radiofrequency ablation, percutaneous ethanol injection, trans-arterial chemo-embolization); FLL clearly visualized at gray scale ultrasound with size \geq 1.5 cm; localized at least 1.5 cm under Glisson's capsule with a maximum depth of 7.5 cm. Patients with failed PSWE acquisition (because of tumor depth or location, or of heart beat in the left lobe) were excluded.

ElastPQ measurements

ElastPQ technique was performed with a Philips EPIQ7 unit (Philips Bothell, WA, USA, C5-2 convex

array transducer) system. Two experienced radiologists (more than 15 years' experience in liver ultrasound examination), who were aware of the patients' clinical histories, performed ultrasound scanning and ElastPQ measurements.

All the ultrasound examinations were performed in patients with fasting conditions, lying in supine position with the right arm in maximum abduction. First, a baseline B-mode ultrasound examination was performed to locate the lesions. We selected a liver area free of visible ducts or vessels. Then, ElastPQ measurements were performed by an intercostal approach, with minimal scanning pressure applied by the operator. A fixed region of interest (ROI) of 0.5 cm \times 1.5 cm was placed with a cursor moved by a trackball. Ten valid ElastPQ measurements with breath holding were performed for each lesion. Each measurement region was positioned in the middle of the ROI. The FLL stiffness was expressed in m/s. Regarding the patient with multiple FLL, only the largest or the most conspicuous one on ultrasound was chosen. Ten additional ElastPQ measurements were performed in the normal surrounding liver parenchyma at least 2 cm from the lesion [24], over the same ultrasound scanning section and on the same depth of the focal liver lesions. The ratios of the elasticity of the lesions to the surrounding liver were determined. Time taken for measurements in addition to B-mode ultrasound were calculated and recorded.

Statistical analysis

Values are reported as mean \pm standard deviation (SD). Mean and median shear wave speed (SWS) of the successful measurements were obtained for each FLLs and the surrounding liver. SWS and SWS ratio in benign and malignant lesions were compared using Mann-Whitney U test. The differences among the SWS of each type of FLLs were evaluated with an analysis of the non-parametric Kruskal-Wallis H test. The optimal elasticity cut-off SWS value and SWS ratio for distinguishing between benign and malignant FLL was assessed by receiver operating characteristic (ROC) curves analysis. The reproducibility of ElastPQ technology was explored by intraclass correlation (ICC) coefficient of reliability analysis. Kappa statistics were calculated to assess inter-observer agreement. Statistical analysis was performed with a computer software package (SPSS, version 21.0, IBM corporation, Armonk, USA). Differences were considered significant when the p value $<$ 0.05.

Results

Final diagnosis of FLLs

ElastPQ measurements were successfully performed in 154 patients. Single FLLs were detected on 120 pa-

Table I. Baseline characteristics of patients

Characteristic	Patients (n = 154)
Age (year)-range (Mean \pm SD)	15-91(55.5 \pm 10.3)
Male/female	108/46
Underlying liver diseases	
Cirrhosis (viral/alcohol)	61
Fibrosis (viral/alcohol)	40
Previous tumor history	6
None	47
AFP (ng/mL)	
\leq 20, n (%)	94 (61.0 %)
21 - 200, n (%)	25 (16.2%)
$>$ 200, n (%)	35 (22.7 %)
CA 19-9 (μ /ml)	
\leq 4.9, n (%)	15 (9.7 %)
$>$ 4.9, n (%)	139 (90.3%)

AFP: alpha-fetoprotein; CA19-9: carbohydrate antigen 19-9

Table II. SWS of malignant and benign FLLs measured by ElastPQ (median/range)

	Lesion diameter (mm)	Lesion depth from skin (mm)	Lesion stiffness (m/s)	Liver stiffness (m/s)	Stiffness ratio (lesion/parenchyma)
Malignant FLL					
HCC (n=104)	50 (15-145)	4.0 (2.6-7.4)	2.63 (1.84-5.68)	1.41 (0.99-2.45)	2.15 (1.56- .92)
ICC (n=7)	42 (17-114)	4.6 (1.9-7.5)	2.42 (1.99-3.31)	1.58 (1.17-2.03)	2.84 (1.7-3.07)
CHC (n=3)	62 (49-68)	4.7 (2.0-7.0)	2.46 (1.32-3.06)	1.27 (1.06-1.62)	2.29 (1.08-2.4)
Sarcoma (n=4)	52 (23-82)	5.0 (2.1-7.3)	2.48 (1.33-2.72)	1.53 (1.44-1.64)	2.03 (1.81-2.11)
Metastasis (n=11)	28 (24-87)	4.3 (1.6-6.4)	2.78 (1.02-3.15)	1.46 (0.82-2.33)	2.12 (1.78-2.5)
Benign FLL					
AML (n=5)	29 (20-48)	3.6 (2.6-7.0)	1.38 (1.15-1.53)	1.52 (1.24-1.58)	0.96 (0.92-1.24)
FNH (n=5)	26 (19-69)	3.8 (2.3-6.5)	1.35 (0.69-2.94)	1.31 (1.15-1.47)	1.03 (0.53-2.15)
Hemangioma (n=11)	87 (53-124)	6.2 (2.7-7.0)	1.5 (0.79-2.61)	1.34 (0.99-1.78)	1.1 (0.57-1.64)
IPT (n=4)	35 (21-103)	5.0 (2.4-6.5)	1.58 (1.4-2.58)	1.6 (1.2-2.2)	1.15 (0.87-1.23)

FLL, focal liver lesion; HCC, hepatocellular carcinoma; CHC, combined hepatocellular carcinoma and intrahepatic cholangiocarcinoma; FNH, focal nodular hyperplasia; ICC, Intrahepatic cholangiocarcinoma; AML, hepatic angiomyolipoma; IPT, Inflammatory pseudotumor.

tients and multiple lesions on 34 patients. The median size of those FLLs was 55 mm (size range: 15 - 145 mm; mean±SD: 55±29 mm).

The reproducibility of ElastPQ technology

In this study, the ICC of 10 measurements of ElastPQ was 0.719 (95% CI: 0.658, 0.776), which indicated the good stability of ElastPQ technology. Substantial inter-reader agreement ($\kappa=0.804$) was achieved.

ElastPQ measurement results

Ten valid ElastPQ measurements were obtained in all subjects. The mean SWS values for malignant and benign FLLs were 2.77±0.68 m/s and 1.57±0.55 m/s, respectively ($p<0.05$). The SWS ratio of each FLL to the surrounding liver parenchyma was 2.23±0.49 for malignant and 1.14±0.36 for benign FLLs ($p<0.05$) (Table II).

The area under the ROC curve in distinguishing malignant from benign lesions was 0.704 for SWS and 0.755 for SWS ratio. The cut off value for differential diagnosis was 2.06 m/s for SWS and 1.67 for SWS ratio (fig 1). The associated sensitivity and specificity were 80.6% and 88.0% for SWS and 67.3% and 71.2% for SWS ratio, respectively.

Time taken for measurement in addition to B-mode ultrasound

The entire ultrasound examination of each patient took less than 10 min. The mean duration of the ElastPQ measurements in addition to B-mode ultrasound were 220±45 sec (range 170-270 sec).

Discussions

SWE technology increases the diagnostic efficiency of ultrasound and makes it possible to evaluate liver stiffness. In contrast to the evaluation of diffuse parenchymal liver disease, little is known about FLLs characterisation using SWE technology. Here we investigated the value of

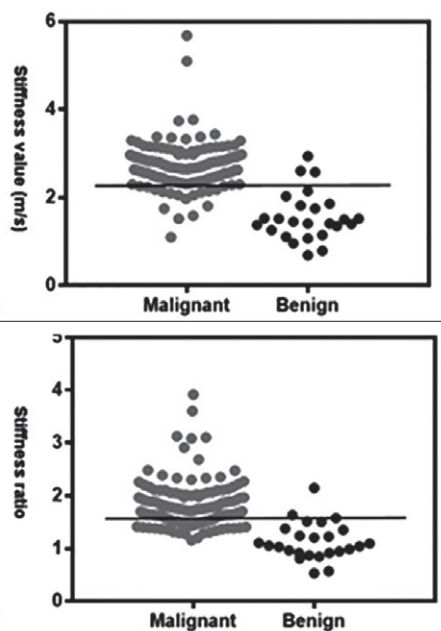


Fig 1. The cut off value for differential diagnosis was 2.06 m/s for shear wave speed (SWS) (a) and 1.67 for SWS ratio (b). The dotted horizontal line at the proposed cut-offs indicate most malignant focal liver lesions are above the cut-off line and those for benign ones are below it.

the ElastPQ technology for the differential diagnosis of benign and malignant FLLs by using histological results as the reference standard.

Previously, ARFI technology turned out as the most widely used method for the evaluation of FLLs. SWS of malignant lesions were proved to be significantly higher compared with benign lesions [17,25,26]. In a recent meta-analysis to evaluate the overall accuracy of elastography in differentiation diagnosis of benign and malignant

FLLs with liver biopsy as the gold standard, ARFI imaging appears to have high sensitivity (85 to 86%) and specificity (80 to 89%) [27,28]. In our current study, both the mean SWS values and the SWS ratio of malignant FLLs were significantly higher than benign ones ($p < 0.05$). The associated sensitivity and specificity were 80.6% and 88.0% for SWS and 67.3% and 71.2% for SWS ratio, respectively. ElastPQ measurement is also a promising non-invasive method which can help differentiating FLLs and preventing unnecessary biopsies in clinical practice.

Some authors thought SWS was more accurate than the stiffness ratio for the differentiation of malignant from benign FLLs, the stiffness ratio might be useful for subclassification of benign and malignant lesions [12,24]. The lesion to parenchyma ratio may be especially of clinical value in the hepatic fibrosis patient population and may also have influence on the reproducibility of stiffness measurement of HCC [16,29]. In our results, the cut-off values for differential diagnosis were 2.06 m/s for SWS and 1.67 for SWS ratio with SWS measured in the liver parenchyma at more than 2 cm from the lesion. The area under the ROC curve in distinguishing malignant from benign FLLs was 0.704 for SWS and 0.755 for SWS ratio. Both the SWS and SWS ratio allowed good diagnostic performance in differentiation malignant and benign FLLs.

Previous studies proved that hepatocellular carcinoma (HCCs) were relatively soft compared with the background liver, when compared with other malignancy groups [14,26,30,31]. HCCs in cirrhotic livers exhibited a relatively uniform and soft interior when compared with the stiff and heterogeneous surrounding parenchyma. In our results, most of the HCCs patients were accompanied with cirrhosis ($n=61$) or fibrosis ($n=40$). Similar results were found by Gallotti et al [14] and by Guibal et al [16].

Stiffness of liver metastasis depends on the amount of fibrous and vessels of the tumor [5] and the type of primary tumor [15]. Metastases which were undergoing treatment with chemotherapy and/or anti-angiogenic therapy could affect their stiffness [12,25]. In accordance with the literature, all metastatic lesions in our study were stiffer than the surrounding liver. The overall SWS of HCCs were lower than that of metastasis. SWE could improve the identify HCC in cirrhotic livers by distinguishing between HCCs and metastasis [14].

For benign FLLs, our study showed that the mean SWS values of malignant FLLs were statistically significantly higher than benign ones including the hemangiomas. ElastPQ measurement might be helpful in differentiation of hepatic hemangioma from malignant FLLs [30-35].

Given the small numbers for individual subgroups, more detail analysis between the FLLs will be considered for our further study.

In a couple of SWE studies of normal liver parenchyma in healthy volunteers, intraobserver reproducibility was excellent in the same day measurement (ICC, 0.87-0.95) or moderate to excellent in the different day measurement (ICC, 0.64-0.84) [36,37]. The reliability analysis in our study showed that ElastPQ for the non-invasive measurement of FLLs had a good reproducibility with ICC 0.719 (95% CI: 0.658, 0.776).

Previously, Ling et al [20] had revealed significant impacts as liver location, breathing phase, and gender on ElastPQ measurement. Park et al [26] found the overall intraobserver reproducibility of SWE in evaluation of FLLs can be affected by lesion depth. Such limitations should be overcome, whenever possible, in order to improve the reproducibility and to ensure the accuracy of ElastPQ measurement [38]. Our practical experiences including: the precise selection of a measurement depth between 4.0-7.5 cm; the precise selection of ROI for SWS measurement with avoidance of necrotic portion, surrounding vascular or bile duct. To perform ElastPQ measurement with patients in the fixed position and holding their breath as requested might also be helpful to insure a good reproducibility.

Our study had some limitations. As the final diagnoses were based on histopathologic results obtained from liver surgeries, only a small number of benign FLLs was included. The overlap of values in patients with benign and malignant lesions needs to be mentioned. In some large FLLs, a different depth of measurement will bring different stiffness results. Prospective and comparative studies with other technologies are required in the future.

In conclusion, our preliminary results suggest ElastPQ is a valid, convenient, non-time consuming and, therefore, comfortable and reproducible non-invasive adjunctive technology for differentiation between malignant and benign FLLs. It is particularly suitable for patients who are not candidates for contrast enhanced imaging although further studies are required.

Conflict of interest: none declared

Acknowledgement: the work was supported by the National Natural Science Foundation of China (No. 81571676)

References

1. European Association for the Study of the Liver, European Organisation for Research and Treatment of Cancer. EASL-EORTC clinical practice guidelines: management of hepatocellular carcinoma. *J Hepatol* 2012;56:908-943.
2. Bolondi L, Gaiani S, Celli N, et al. Characterization of small nodules in cirrhosis by assessment of vascularity: the

- problem of hypovascular hepatocellular carcinoma. *Hepatology* 2005;42:27-34.
3. Ozmen E, Adaletli I, Kayadibi Y, et al. The impact of shear wave elastography in differentiation of hepatic hemangioma from malignant liver tumors in pediatric population. *Eur J Radiol* 2014;83:1691-1697.
 4. Bamber J, Cosgrove D, Dietrich CF, et al. EFSUMB guidelines and recommendations on the clinical use of ultrasound elastography. Part 1: Basic principles and technology. *Ultraschall Med* 2013;34:169-184.
 5. Cosgrove D, Piscaglia F, Bamber J, et al. EFSUMB guidelines and recommendations on the clinical use of ultrasound elastography. Part 2: Clinical applications. *Ultraschall Med* 2013;34:238-253.
 6. Ferraioli G, Tinelli C, Lissandrin R, et al. Point shear wave elastography method for assessing liver stiffness. *World J Gastroenterol* 2014;20:4787-4796.
 7. Kapetas P, Pinker-Domenig K, Woitek R, et al. Clinical application of Acoustic Radiation Force Impulse Imaging with Virtual Touch IQ in breast ultrasound: diagnostic performance and reproducibility of a new technique. *Acta Radiol* 2017;58:140-147.
 8. Correas JM, Tissier AM, Khairoune A, et al. Prostate cancer: diagnostic performance of real-time shear-wave elastography. *Radiology* 2015;275:280-289.
 9. Bhatia KS, Tong CS, Cho CC, Yuen EH, Lee YY, Ahuja AT. Shear wave elastography of thyroid nodules in routine clinical practice: preliminary observations and utility for detecting malignancy. *Eur Radiol* 2012;22:2397-2406.
 10. Suh CH, Choi YJ, Baek JH, Lee JH. The diagnostic performance of shear wave elastography for malignant cervical lymph nodes: A systematic review and meta-analysis. *Eur Radiol* 2017;27:222-230.
 11. D'Onofrio M, De Robertis R, Crosara S, et al. Acoustic radiation force impulse with shear wave speed quantification of pancreatic masses: A prospective study. *Pancreatol* 2016;16:106-109.
 12. Guo LH, Wang SJ, Xu HX, et al. Differentiation of benign and malignant focal liver lesions: value of virtual touch tissue quantification of acoustic radiation force impulse elastography. *Med Oncol* 2015;32:68.
 13. Heide R, Strobel D, Bernatik T, Goertz RS. Characterization of focal liver lesions (FLL) with acoustic radiation force impulse (ARFI) elastometry. *Ultraschall Med* 2010;31:405-409.
 14. Gallotti A, D'Onofrio M, Romanini L, Cantisani V, Pozzi Mucelli R. Acoustic Radiation Force Impulse (ARFI) ultrasound imaging of solid focal liver lesions. *Eur J Radiol* 2012;81:451-455.
 15. Frulio N, Laumonier H, Carteret T, et al. Evaluation of liver tumors using acoustic radiation force impulse elastography and correlation with histologic data. *J Ultrasound Med* 2013;32:121-130.
 16. Guibal A, Boullaran C, Bruce M, et al. Evaluation of shear-wave elastography for the characterisation of focal liver lesions on ultrasound. *Eur Radiol* 2013;23:1138-1149.
 17. Park H, Park JY, Kim DY, et al. Characterization of focal liver masses using acoustic radiation force impulse elastography. *World J Gastroenterol* 2013;19:219-226.
 18. Ronot M, Di Renzo S, Gregoli B, et al. Characterization of fortuitously discovered focal liver lesions: additional information provided by shearwave elastography. *Eur Radiol* 2015;25:346-358.
 19. Sporea I, Bota S, Gradinaru-Tascau O, Şirli R, Popescu A. Comparative study between two point Shear Wave Elastographic techniques: Acoustic Radiation Force Impulse (ARFI) elastography and ElastPQ. *Med Ultrason* 2014;16:309-314.
 20. Ling W, Lu Q, Quan J, Ma L, Luo Y. Assessment of impact factors on shear wave based liver stiffness measurement. *Eur J Radiol* 2013;82:335-341.
 21. Ma JJ, Ding H, Mao F, Sun HC, Xu C, Wang WP. Assessment of liver fibrosis with elastography point quantification technique in chronic hepatitis B virus patients: a comparison with liver pathological results. *J Gastroenterol Hepatol* 2014;29:814-819.
 22. Ling W, Lu Q, Lu C, et al. Effects of vascularity and differentiation of hepatocellular carcinoma on tumor and liver stiffness: in vivo and in vitro studies. *Ultrasound Med Biol* 2014;40:739-746.
 23. Chen S, Sanchez W, Callstrom MR, et al. Assessment of liver viscoelasticity by using shear waves induced by ultrasound radiation force. *Radiology* 2013;266:964-970.
 24. Lu Q, Ling W, Lu C, et al. Hepatocellular carcinoma: stiffness value and ratio to discriminate malignant from benign focal liver lesions. *Radiology* 2015;275:880-888.
 25. Goya C, Hamidi C, Yavuz A, et al. The Role of Acoustic Radiation Force Impulse Elastography in the Differentiation of Infectious and Neoplastic Liver Lesions. *Ultrason Imaging* 2015;37:312-322.
 26. Park HS, Kim YJ, Yu MH, Jung SI, Jeon HJ. Shear Wave Elastography of Focal Liver Lesion: Intraobserver Reproducibility and Elasticity Characterization. *Ultrasound Q* 2015;31:262-271.
 27. Ma X, Zhan W, Zhang B, et al. Elastography for the differentiation of benign and malignant liver lesions: a meta-analysis. *Tumour Biol* 2014;35:4489-4497.
 28. Ying L, Lin X, Xie ZL, Tang FY, Hu YP, Shi KQ. Clinical utility of acoustic radiation force impulse imaging for identification of malignant liver lesions: a meta-analysis. *Eur Radiol* 2012;22:2798-2805.
 29. Tian WS, Lin MX, Zhou LY, et al. Maximum Value Measured by 2-D Shear Wave Elastography Helps in Differentiating Malignancy from Benign Focal Liver Lesions. *Ultrasound Med Biol* 2016;42:2156-2166.
 30. Cho SH, Lee JY, Han JK, Choi BI. Acoustic radiation force impulse elastography for the evaluation of focal solid hepatic lesions: preliminary findings. *Ultrasound Med Biol* 2010;36:202-208.
 31. DeWall RJ, Bharat S, Varghese T, Hanson ME, Agni RM, Kliewer MA. Characterizing the compression-dependent viscoelastic properties of human hepatic pathologies using dynamic compression testing. *Physics Med Biol* 2012;57:2273-2286.

32. Davies G, Koenen M. Acoustic radiation force impulse elastography in distinguishing hepatic haemangiomas from metastases: preliminary observations. *Br J Radiol* 2011;84:939-943.
33. Zhang P, Zhou P, Tian SM, Qian Y, Deng J, Zhang L. Application of acoustic radiation force impulse imaging for the evaluation of focal liver lesion elasticity. *Hepatobiliary Pancreat Dis Int* 2013;12:165-170.
34. Kim JE, Lee JY, Bae KS, Han JK, Choi BI. Acoustic radiation force impulse elastography for focal hepatic tumors: usefulness for differentiating hemangiomas from malignant tumors. *Korean J Radiol* 2013;14:743-753.
35. Brunel T, Guibal A, Boullaran C, et al. Focal nodular hyperplasia and hepatocellular adenoma: The value of shear wave elastography for differential diagnosis. *Eur J Radiol* 2015;84:2059-2064.
36. Hudson JM, Milot L, Parry C, Williams R, Burns PN. Inter- and intra-operator reliability and repeatability of shear wave elastography in the liver: a study in healthy volunteers. *Ultrasound Med Biol* 2013;39:950-955.
37. Ferraioli G, Tinelli C, Zicchetti M, et al. Reproducibility of real-time shear wave elastography in the evaluation of liver elasticity. *Eur J Radiol* 2012;81:3102-3106.
38. Ferraioli G, Filice C, Castera L, et al. WFUMB guidelines and recommendations for clinical use of ultrasound elastography: Part 3: liver. *Ultrasound Med Biol* 2015;41:1161-1179.