

## Ultrasound examination of normal liver

**Alina Popescu, Ioan Sporea**

Department of Gastroenterology and Hepatology, University of Medicine and Pharmacy Timișoara

### Abstract

The liver is a very accessible organ to ultrasound examination due to its position, structure and dimensions; liver pathology represents an important part of ultrasound examination of the abdomen, because it is able to primarily evaluate a liver tumor, or it allows the evaluation of a case with abnormal liver tests or the evaluation of the pain of the right upper quadrant.

A correct examination of the liver requires the patient's fasting 6 to 8 hours before the examination. The examination starts with the patient laying on his back and then rotate the patient on left lateral decubitus.

We use sagittal, transversal, right oblique subcostal sections for the liver examination, as well as intercostal sections. In each and every section we evaluate the homogeneity and the texture of the liver structure, the presence or the absence of focal lesions, the liver surface, and the patency of vessels: portal vein and suprahepatic veins.

**Key words:** liver, correct examination, ultrasonography

### Rezumat

Ficatul este un organ parenchimos foarte accesibil examinării ecografice prin poziție, structură și dimensiuni, patologia hepatică reprezentând în același timp o proporție importantă din indicațiile de examinare ecografică, fie că este vorba de elucidarea naturii unei formațiuni tumorale hepatice, fie de evaluarea pentru teste hepatice anormale sau pentru durere în hipocondrul drept.

Pentru examinarea corectă ecografică a ficatului, ideal este ca pacientul să fie a jeun sau să nu se fi alimentat cu 6-8 ore înainte de examinare. Se începe examinarea în poziție de decubit dorsal, care se poate completa ulterior cu examinarea în decubit lateral stâng.

Pentru examinarea ficatului folosim secțiuni sagitale, transversale și secțiuni oblice subcostale drepte, fără a uita secțiunile intercostale, putând începe examinarea cu oricare dintre acestea. În oricare secțiune examinăm vom urmări omogenitatea și textura structurii hepatice, prezența sau nu de formațiuni circumscrise, suprafața hepatică, patența vaselor ce sunt examinate odată cu ficatul, respectiv vena portă și venele suprahepatice.

**Cuvinte cheie:** ficat, examinare corectă, ecografie

Ultrasound examination is an imaging method easy to use by the practitioner and extremely useful, due to the information offered, but it is an operator-depending method, in which the examination technique might be the key of a correct diagnosis.

The liver is a very accessible organ to ultrasound examination due to its position, structure and dimensions;

liver pathology represents an important part of ultrasound examination of the abdomen, because it is able to primarily evaluate a liver tumor, or it allows the evaluation of a case with abnormal liver tests or pain of the right upper quadrant.

In order to have a quality ultrasound window it is necessary for the patient to perform a deep inhale and keep it in for a few seconds, while the examiner evaluates the liver structure.

The examination methods recommended are: grayscale examination, harmonic imaging, as well as Color Doppler, Power or Spectral Doppler. We use a transducer for the abdomen examination with a variable frequency, be-

Address for correspondence: Alina Popescu  
Barbu Iscovescu str. 8, Sc. A, Ap. 7  
300561 Timișoara, Romania  
Tel: 0748331233  
Fax: 0256488003  
Email: alinamircea.popescu@gmail.com

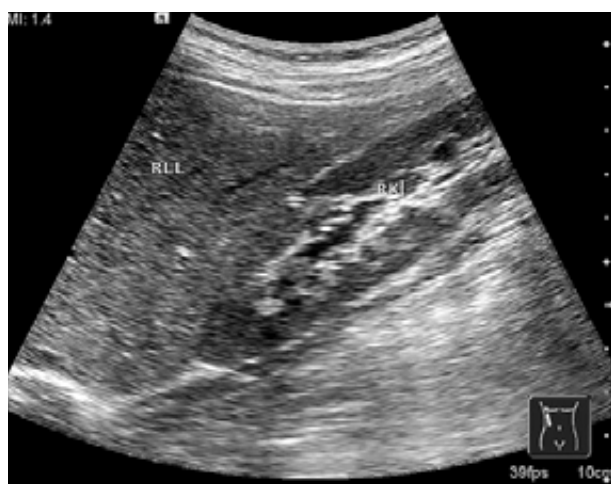tween 2-5 MHz, adjusted according to the characteristics of the subject (lower frequency for a better penetrability). If we are interested in the details of the liver surface or the superficial part of the liver higher, frequency transducers might be needed (4-8 MHz).

In order to be able to integrate the information in a clinical context it is recommended to start the ultrasound examination with a brief anamnesis, as well as with a physical examination of the abdomen,

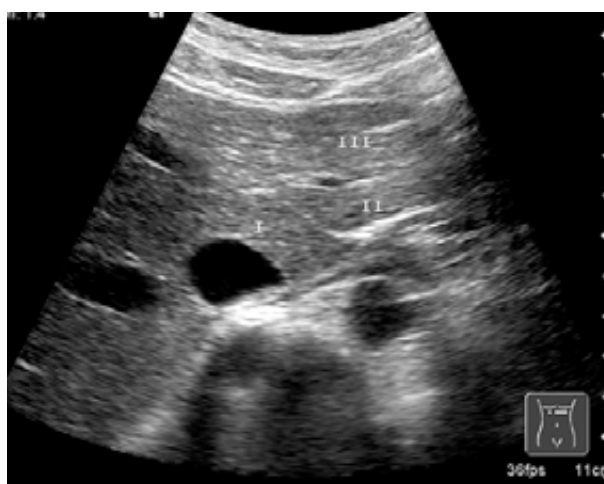We use sagittal, transversal, right oblique subcostal sections for the liver examination, as well as intercostal sections. In each and every section we evaluate the homogeneity and the texture of the liver structure, the presence or the absence of focal lesions, the liver surface,

and the patency of vessels: portal vein and suprahepatic veins. The liver echogenicity is described compared to the right kidney cortical area, which in normal conditions are pretty much similar (fig 1).

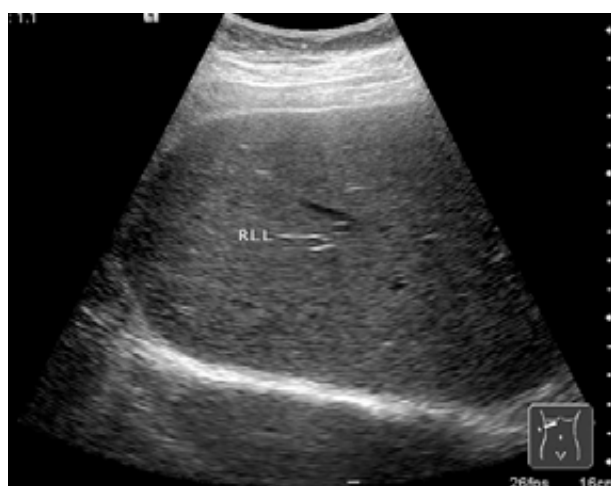The oblique subcostal sections starting from the epigastrium examine the left liver lobe from the inferior and up to the superior side of it in order to cover the entire structure of the left liver lobe (fig 2). By moving the transducer towards the right hypocondrium we can examine the right liver lobe (fig 3). In this oblique subcostal section we can also see the portal bifurcation with its right and left branches (fig 4), while in a superior plan we can find the suprahepatic veins together with the inferior vena cava (fig 5, 6, 7).



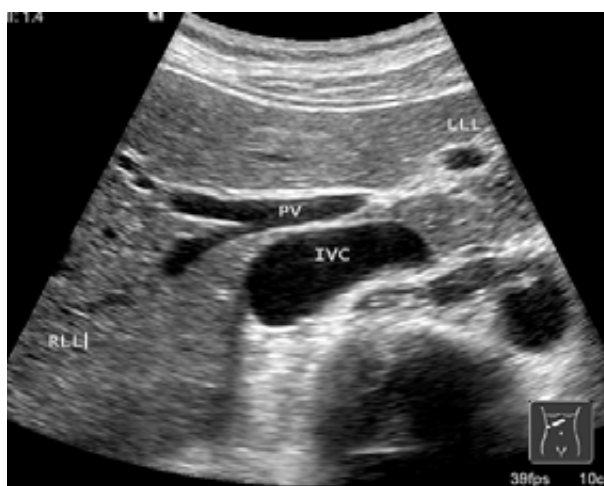**Fig 1.** Left liver lobe, transversal section with the caudate lobe near the inferior vena cava and the segments II and III.



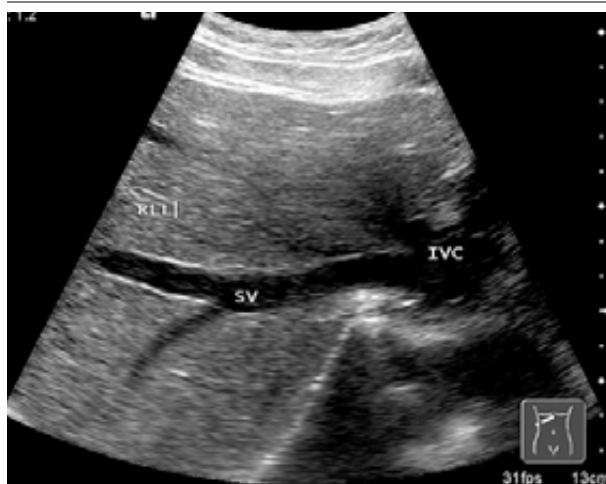
**Fig 2.** Right subcostal section with the visualization of the bifurcation of the portal vein, inferior vena cava in posterior and left and right liver lobes.



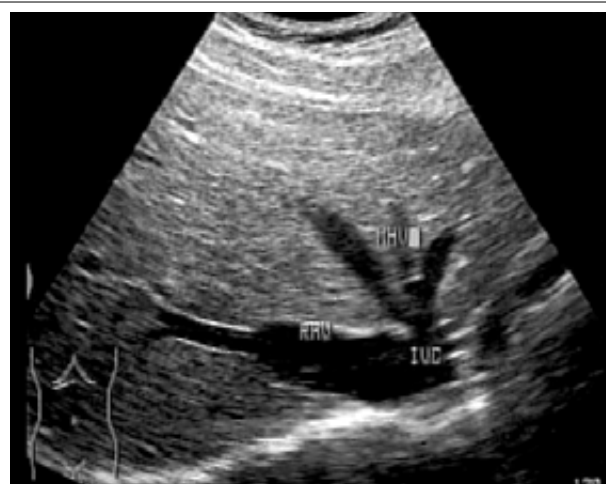**Fig 3.** Right subcostal section in the right liver lobe with the visualization of diaphragm posterior.



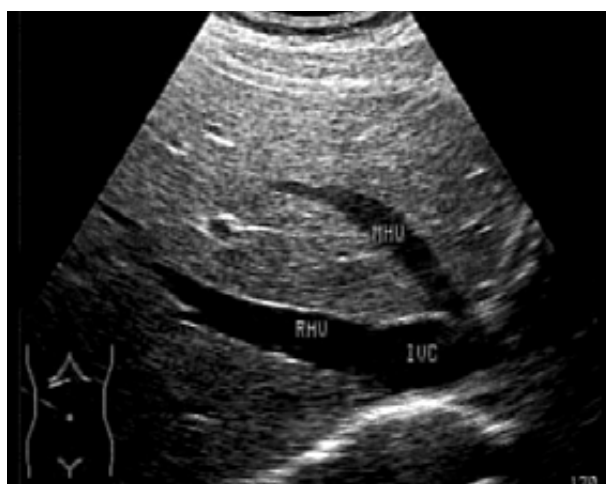**Fig 4.** Right subcostal section in the right liver lobe with the visualization of a branch of the suprahepatic veins and the inferior vena cava.



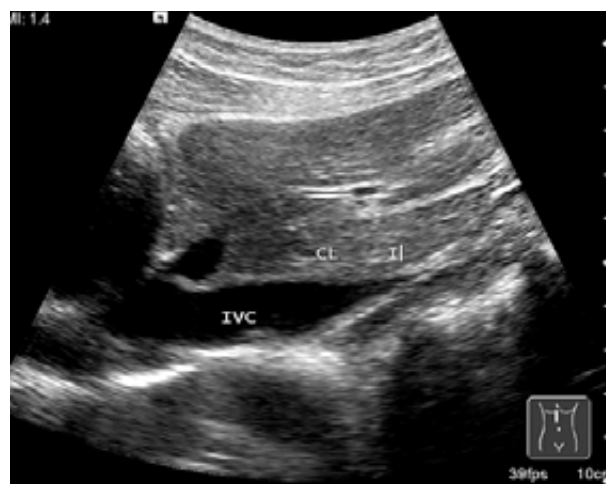
**Fig 5.** Right subcostal section in the right liver lobe with the visualization of the suprahepatic veins.



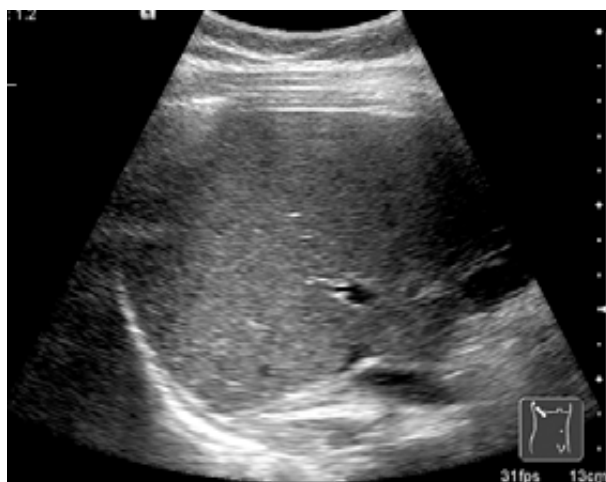**Fig 6.** Right subcostal section in the right liver lobe with the visualization of the suprahepatic veins.



**Fig 7.** Sagittal section in the right upper quadrant with the visualization of the right liver lobe and the right kidney.



**Fig 8.** Sagittal section in the epigastrium with the visualization of the caudate lobe.



**Fig 9.** Intercoastal section through the right liver lobe.

In a sagittal section starting also from the epigastrium, we can locate the left liver lobe as well as the caudate lobe standing in front of the inferior vena cava (fig 8). It is recommended to measure the antero-posterior diameter of the caudate lobe as it can be enlarged in case of liver cirrhosis (usually more than 35 mm). By moving towards the right flank we will scan the entire liver in a sagittal section encountering also the gallbladder.

It is also recommended to perform an intercostal examination while the patient is in lateral decubitus in order to observe the liver dome (fig 9).

Anatomically speaking the liver is divided into 2 lobes: the right and the left lobe by the falciform ligament. The branches of the portal system mark the limits of 8 liver segments according to Couinaud, allowing a more precise localization of a focal liver lesion. The cau-

dat lobe (segment I) is considered a separate structure from the 2 lobes, being located between the inferior vena cava – posterior and the venous ligament – anterior. The left liver lobe contains segment II – posterior and segment III – anterior. The right liver lobe contains segments VII and VIII – superior and segments V and VI – inferior and segment IV – medial.

The correct examination of the liver implies first of all the examination of the entire organ in order to avoid possible misdiagnosis of liver lesions, as well as establishing the homogeneity and the characteristics of the

liver structure, not to mention the description of possible pathological lesions.

### **Selective references**

1. Ioan Sporea, Cristina Cijevschi Prelipcean. Ecografia abdominală în practica clinică, Ediția a II-a, Editura Mirton, Timișoara Editura Mirton, 2004:9-99.
2. M. Høgholm Pedersen, M. Bachmann Nielsen, B. Skjoldbye. Basics of clinical ultrasound, Ed. Ultrapocketbooks, Copenhagen, 2006:41-53.