

Cystic echinococcosis, review and illustration of non-hepatic manifestations

Christoph F. Dietrich^{1,2}, Wiem Douira-Khoms³, Hassen Gharbi⁴, Malay Sharma⁵, Xin Wu Cui⁶, Zeno Sparchez⁷, Joachim Richter⁸, Adnan Kabaalioglu⁹, Nathan S.S. Atkinson¹⁰, Dagmar Schreiber-Dietrich¹¹, Yi Dong¹²

¹Department Allgemeine Innere Medizin (DAIM), Kliniken Hirslanden, Beau Site, Salem und Permanence, Bern, Switzerland, ²Sino-German Research Center of Ultrasound in Medicine, The First Affiliated Hospital of Zhengzhou University, Zhengzhou, China, ³Hopital d'Enfants Bechir Hamza, Tunis, Tunisia, ⁴Department of Radiologie, Ibn Zohr Clinic, Tunis, Tunisia, ⁵Department of Gastroenterology, Jaswant Rai Speciality Hospital, Meerut, India, ⁶Department of Medical Ultrasound, Tongji Hospital, Tongji Medical College, Huazhong University of Science and Technology, Wuhan, China, ⁷3rd Medical Department, University of Medicine and Pharmacy "Iuliu Hatieganu", Institute for Gastroenterology and Hepatology "O. Fodor" Cluj-Napoca, Romania, ⁸Institute of Tropical Medicine and International Health, Charité Universitätsmedizin, Berlin, Germany, ⁹Department of Radiology, Koç University Hospital-Istanbul, Turkey, ¹⁰Department of Gastroenterology, Waitemata District Health Board, Auckland, New Zealand, ¹¹Localinomed Bern, Switzerland, ¹²Department of Ultrasound, Zhongshan Hospital, Fudan University, Shanghai, China

Abstract

Cystic echinococcosis (CE) or hydatidosis (hydatid cysts), is an infection with a wide spectrum of manifestations, from asymptomatic infection to fatal disease. Ultrasound (US) allows screening, diagnosis, differential diagnosis, treatment guidance and follow-up of CE under many circumstances. Hydatid cysts are predominantly observed in the liver but many other organs can be involved. As part of a series of publications, herewith we present a review describing the characteristic imaging features of the broad variety of organs which can be involved

Keywords: cystic echinococcosis (CE); hydatidosis; ultrasound (US); non-liver; imaging

Introduction

Cystic echinococcosis (CE) or hydatidosis (hydatid cysts), is an infection caused by the larval stage (metacystode) of the cestode (tapeworm) *Echinococcus granulosus*. In humans, it may result in a wide spectrum of manifestations, from asymptomatic infection to fatal disease.

The clinical manifestations [1] and imaging features of modern imaging for liver CE has been recently described [2]. In brief, infection most commonly affects the liver without generating symptoms. The evolution of cysts can be defined into stages according to the WHO classification [3] which updated Gharbi's work [4]; from active stages of simple cysts and daughter cysts, those with the pathognomonic 'water-lily' sign, or daughter cysts with solid or calcified components, to non-viable forms with increasing fibrosis and calcification [1]. As cysts grow, local compressive effects and infiltration of surrounding structures can precipitate symptoms and a broad range of local complications [2]; secondary infection, rupture into the biliary tree, the peritoneal cavity, or through the diaphragm to the thorax.

Received 20.12.2019 Accepted 24.02.2020

Med Ultrason

2020, Vol. 22, No 3, 319-324

Corresponding author: Prof. Dr. med. Christoph F. Dietrich
Department Allgemeine Innere Medizin
(DAIM), Kliniken Hirslanden, Beau Site,
Salem und Permanence, Bern, Switzerland
E-mail: c.f.dietrich@googlemail.com

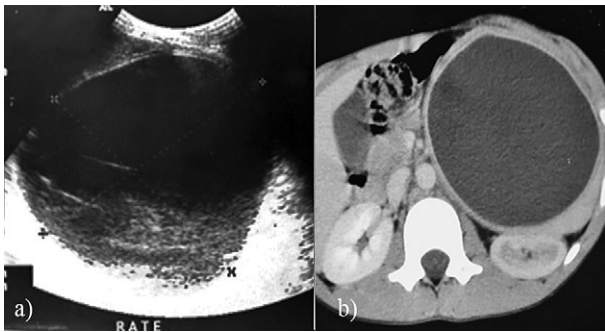


Fig 1. Splenic hydatid cyst. A 12-year-old girl presents with a painful mass in the left hypochondrium: a) oblique ultrasound scan; b) axial contrast CT image; A large fluid collection, rounded, with well-defined borders and hydatid sand are well seen by US (type I Gharbi's classification) within the spleen.

In this review, we want to describe the wide variety of organ involvement of CE and to demonstrate characteristic imaging features.

Pancreatic involvement

Infection of the pancreas by hydatid cysts is very rare, even in endemic areas, where full body imaging is necessary for accurate diagnosis, particularly in instances of atypical deposits. Even when surgery is not possible, chemotherapy as treatment or prophylaxis against recurrence can be effective [5,6]. Migration to the pancreas occurs predominantly via hematological spread or peripancreatic lymphatic invasion. Very rare cases are reported via retroperitoneal spread [6]. Within the pancreas, the head is most frequently involved (57%), followed by the body (24%) and the tail (19%) [7]. Pancreatic hydatid cysts can cause non-specific symptoms, commonly related to the location and size of the cyst, but are usually asymptomatic. Those in the head of the pancreas can cause obstructive jaundice or pancreatitis. Large cysts in the body or tail of pancreas, most commonly cause abdominal pain [8].

The imaging features reported for pancreatic hydatid cysts include contrast enhanced computer tomography (CE-CT) demonstrating a hypodense mass in the uncinate process with a suggestion of hyperdense/enhancing curvilinear densities, magnetic resonance imaging (MRI) showing a non-enhancing cystic mass, and endoscopic ultrasound which might demonstrate a cystic structure with curvilinear floating membranes consistent with the water lily sign, pathognomonic of hydatid disease [9].

Splenic manifestations

Splenic involvement is an uncommon manifestation of hydatid cysts, accounting for only 4% of all abdominal cases. Most cases of splenic involvement are seen in conjunction with hepatic or peritoneal HD, with splenic seeding from primary cyst rupture and/or contiguous cyst

growth [10,11]. The clinical manifestations include non-specific left upper abdominal pain, right upper abdominal pain with dyspepsia or they may be asymptomatic [12].

The imaging findings of splenic hydatid cysts are similar to those of hydatid cysts seen in other abdominal viscera and range from purely cystic lesions to completely solid or calcified masses (fig 1). A solitary or multi-locular cystic lesion is the most common finding. Heavily calcified masses are indicative of non-viable cysts. Multiple lesions have also been reported in the spleen [10,13]. A spleen-saving approach is likely an effective method for the removal of CE spleen cysts given that it is a quick procedure and preserves the function of the spleen. Total splenectomy procedures may be required for particularly large, centrally located cysts [14].

Pelvic manifestation

Pelvic echinococcosis can be either primary or secondary, but are extremely rare, with an incidence of only 0.2-2.25%. Secondary pelvic hydatid cysts are more common and occur following the cyst rupture of a primary hepatic, splenic or mesenteric lesion. If no other associated cyst in the abdomen is identified, a pelvic hydatid cyst is considered to be primary [15]. Pelvic lesions present with symptoms usually due to mass effect. These may be confused with obstructive uropathy (due to compression of the urinary tract), ovarian cysts, appendicitis or even pelvic sepsis (when they rupture). An ultrasound followed by a CECT scan is usually required for diagnosis. MRI in most instances is not required, as it offers little additional information over CT [15] (fig 2). Hydatid cysts in the uterus can mimic other conditions such as multi-cystic ovarian tumor, hemorrhagic ovarian cyst,

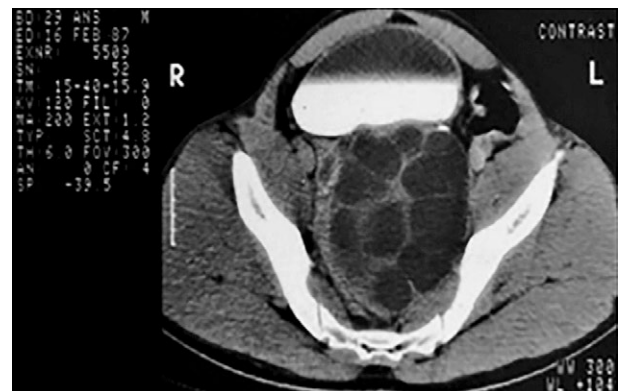


Fig 2. Pelvic hydatid cysts. Gharbi's classification type III. A 29-year-old woman presents with hypogastric pain and frequency of micturition. Axial contrast enhanced CT (CE-CT) demonstrates a large multi-loculated cystic lesion in the retrovesical region of the pelvis, displacing the bladder anteriorly. No mural nodule, soft tissue component or calcifications were seen within the lesion.

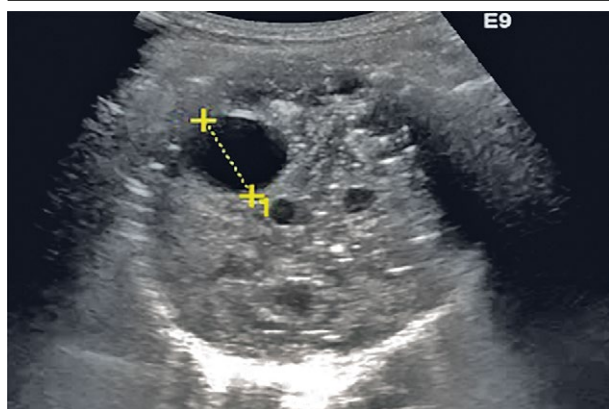


Fig 3. Lung hydatid cyst with daughter cyst.

endometrioma, cystadenoma, leiomyoma, etc [16]. Primary ovary hydatid disease in postmenopausal women must be carefully differentiated from ovarian malignancy [17,18].

Retrovesicular hydatid cysts may have a varied and non-specific presentation. Ultrasound and CECT are both excellent imaging modalities for the detection of urinary tract hydatid cysts. The treatment of choice in this context is principally a careful and complete surgical excision, which can be achieved either by open or laparoscopic approaches [19].

Lung involvement

The lung is the second most common organ involved in adults, but the most common infected organ in children. The majority of patients with even multi-locular lung involvement are asymptomatic, particularly in children and young patients. However, chest pain, cough,

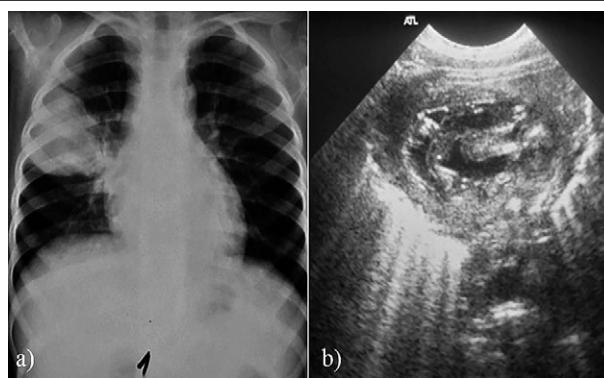


Fig 4. Hydatid cyst of the right lung. A 6-year-old boy presents with dry cough and mild fever without chest pain, dyspnoea or weight loss: (a) anteroposterior view of chest x-ray shows a well-defined round radio-opacity in the right upper zone; (b) transthoracic ultrasound demonstrates the coiled floating membrane within a fluid collection - pathognomonic features of Gharbi's classification type IV hydatid cyst.

dyspnoea and hemoptysis may occur. A single cyst may be found in 50% of cases, two in 20% and multiple cysts in 30%. Cysts are usually located in the lower lobes and may grow up to 10 cm [20-22]. Most of the cysts are Gharbi 1 or 2 cysts, calcification and daughter cyst formation being rare in lung hydatidosis [21] (fig 3). The use of lung ultrasound so far is limited but promising [23-27].

Pulmonary hydatid cysts are usually diagnosed with plain radiography and then further characterized by CT. US can depict lesions peripherally located or with pleural contact. The “wall sign” describes a double-layered wall in univesicular cysts and a double-layered septum in cases of multi-vesicular cysts [22] (fig 4). It has been

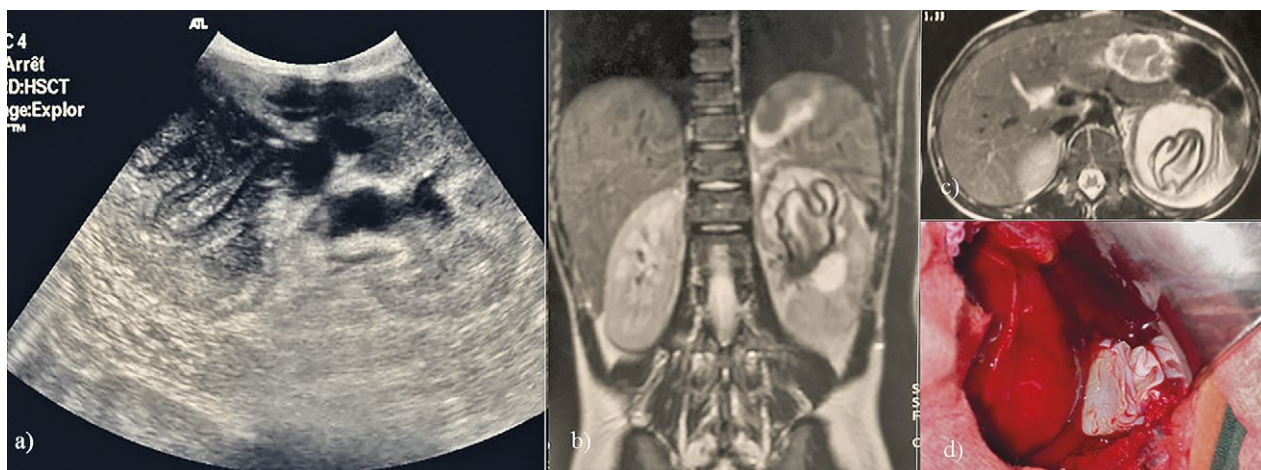


Fig 5. Left renal hydatid cyst with floating membranes following rupture of the cyst into urinary tract. A 10-year-old boy presented with left lumbar pain and intermittent passage of grape-like structures in the urine for the last three months. Sagittal ultrasound scan shows a complex cystic lesion of the left kidney with hydronephrosis (a). MRI coronal (b) and axial (c) T2-weighted images show the detached germinative membrane, intra-operative view of total external capsule excision (d).

reported to have a specificity of nearly 100% for diagnosing pulmonary hydatid cysts [3]. In peripheral pulmonary disease, ultrasound may be an appropriate alternative to CT for children, as an easily available and non-irradiating modality [21]. The majority of patients with even multi-locular lung involvement are asymptomatic, particularly in children and young patients [28-30]. However, chest pain, cough, dyspnea and hemoptysis may occur. Complications include rupture with spilling of larva fragments and protoscolices into the bronchial tree and pleural cavity, bacterial super-infection, abscess formation, empyema, pneumothorax and systemic spread. Concomitant liver involvement occurs in 20% of patients, and is more common in children than adults [27,28,30].

Kidney and urinary tract involvement

Hydatid cysts of the kidney are rare, occurring in 3% of cases [20]. They may present with acute renal colic and hydatiduria. Specific features of urinary hydatid cyst may result after a cyst ruptures into the collecting system [10,31]. Involvement of the kidney is mainly due to parasitic dissemination through the portal venous system and retroperitoneal lymphatics to reach the renal fossae [32]. Renal hydatid cysts are generally located in the upper or lower pole of the kidney cortex, usually solitary and can grow up to 10 cm without symptoms. Complications include infection and rupture (18% of cases) into the urinary tract [33] (fig 5). The clinical manifestations of renal hydatid cyst otherwise nonspecific; back pain, dysuria, and hematuria are reported most frequently. The US signs are similar to hepatic hydatid cysts [20]. In cases of multi-locular cysts, differentiation from simple renal cysts, cystic nephroma or renal cell carcinoma is required [34,35] (fig 6-8). A unilocular cyst with a calcified rim or a multilocular cystic lesion with heterogeneity on CT suggests hydatid disease [36].

Other organ involvement

Involvement of organs other than those described above are even less frequently encountered but significant morbidity and mortality occurs. Systemic infiltrations affecting the central nervous system, musculoskeletal system, subcutaneous cyst with skin involvement, heart and pericardium with pericardial effusion or tamponade, ocular cysts and appendix involvement [37,38] can occur. Cysts are mostly asymptomatic, so that patients often present with clinical evidence of mass or vague symptoms. This explains the common delay to diagnosis, and lack of data on correlation to the real moment of infection [39]. The diagnosis is confirmed by clinical evidence, medical history including epidemiology and radiological support. US is frequently considered the gold standard in imaging of the cyst, whilst CT scan and MRI often offer improved definition of anatomic relations [40].

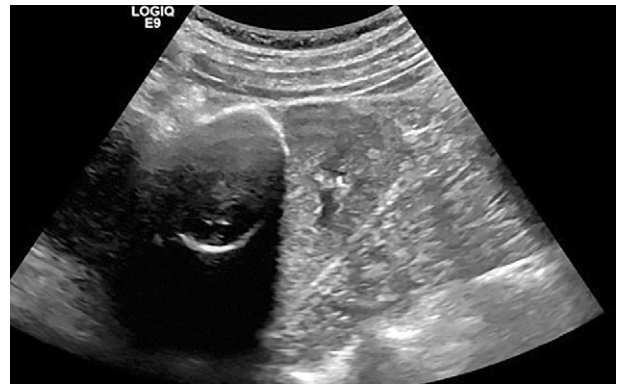


Fig 6. Hydatid cyst of the left kidney in a young boy: axial contrast CT image shows a fluid collection with multiple secondary vesicles (Gharbi's classification type III) within the left renal parenchyma.

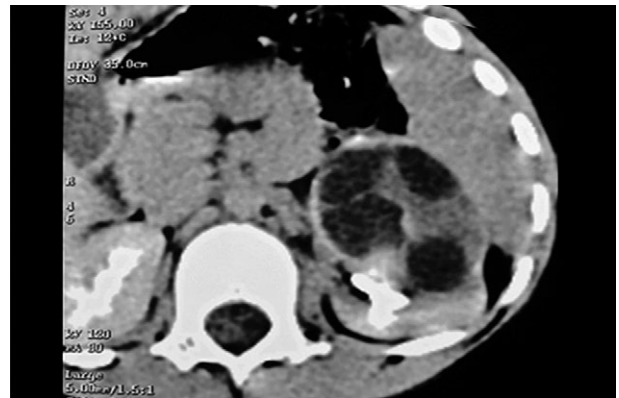


Fig 7. Left renal hydatid cyst. Another 9-year-old boy presented with left flank pain. A hydatid cyst of the left kidney type III of Gharbi's classification was identified: axial contrast CT image shows a well-defined complex cystic mass within the left renal parenchyma. The mass contains multiple smaller cysts with variable but predominantly low attenuation fluid matrix.

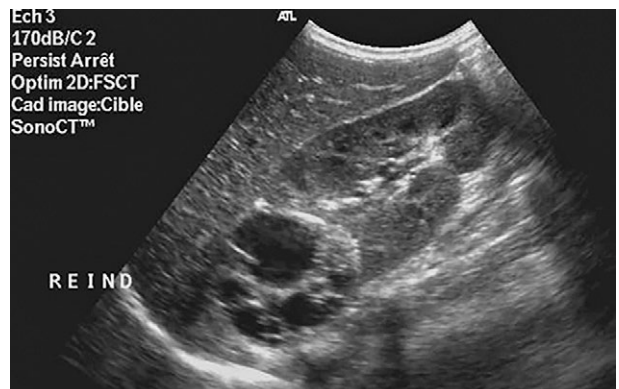


Fig 8. Renal hydatid cyst of the right kidney type III of Gharbi's classification was identified in a 13-year-old boy who presented with pain in the right flank: longitudinal ultrasound scan shows a multi-septated cystic structure in the upper pole of the right kidney.

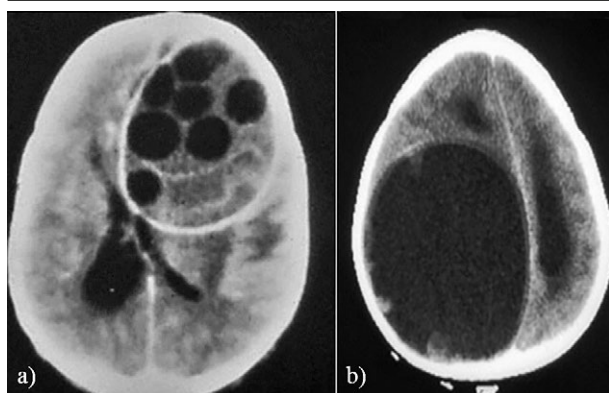


Fig 9. a) Intracranial hydatid cyst type III Gharbi's classification. A 24-year-old man presents with headache and vomiting for the last month: axial contrast CT scan shows a large left frontal multi-locular cyst with presence of daughter cysts. Note the mass effect towards the right frontal horn and right lateral ventricle with shift of midline but without pericysticoedema; b) Intracranial hydatid cyst type I Gharbi's classification. An 8-year-old boy presents with a seizure: axial contrast CT scan showing large right parietal lobe cyst (10 x 8 cm) with thin regular wall, displaying marked compression of left lateral ventricle with midline shift.

Brain

Multiple intracranial lesions can result from the rupture of an initial single intracranial cyst (in cystic echinococcosis) or from dissemination of systemic disease of the lung, liver or heart (cystic and alveolar echinococcosis) [41]. The two main subtypes, cystic and alveolar echinococcosis, present differently and have distinct imaging features in the brain. Most cases of intracranial cystic echinococcosis present with features of a space-occupying lesion such as headache, vomiting or focal neurological signs [40]. On CT or MR imaging, cystic echinococcosis characteristically appears as a well-defined, thin-walled cerebrospinal fluid-signal cyst, which is usually solitary but may contain multiple daughter cysts. There is usually no surrounding oedema unless secondarily infected [41] (fig 9).

Orbit and eye

Head and neck involvement of echinococcosis is a rare entity and extension of the hydatid cyst into the intraorbital region or infiltrating into the surrounding orbital bone is even rarer [42]. Clinical and radiological findings are important but may not be sufficient in the preoperative diagnosis. Proptosis may be seen with orbital or infratemporal hydatidosis, and although rare should be considered a differential diagnosis [43]. The role of a radiologist is crucial in expediting the diagnosis of orbital lesions with the help of characteristic imaging features on ultrasound, CT or MRI. These also help identify complications where formulation of an early and ef-

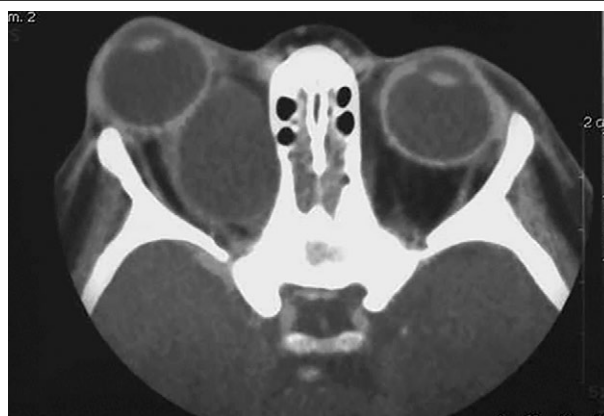

Fig 10. Orbital hydatid cyst type I Gharbi's classification. An 18-year-old boy presented with progressive right eye swelling and visual deterioration: axial contrast CT scan shows a well-demarcated intraconal cystic lesion, located in the posterosuperior region of right bulbous oculi. Note the mass effect on the optic nerve. Orbital hydatid cysts generally occur in a posterior position.

fective management strategy is vital for preserving vision [44] (fig 10).

Conclusion

Echinococcosis hybrid cystic lesions are frequently encountered in clinical practice in specific geographic areas of the world. Hydatidosis affects multiple organs and has diverse imaging presentations. Application of the WHO classification system outside of the liver is of practical benefit. Knowledge of the specific imaging features enables accurate diagnosis, facilitates appropriate management and helps avoid complications.

Acknowledgement: The authors thank the Bad Mergentheimer Leberzentrum e.V. for support.

Conflict of interest: none

References

1. Brunetti E, Tamarozzi F, Macpherson C, et al. Ultrasound and Cystic Echinococcosis. *Ultrasound Int Open* 2018;4:E70-E78.
2. Dietrich CF, Douira-Khomsy W, Gharbi H, et al. Cystic and alveolar echinococcosis of the hepatobiliary tract - the role of new imaging techniques for improved diagnosis. *Med Ultrason* 2020;22;76-86.
3. WHO Informal Working Group. International classification of ultrasound images in cystic echinococcosis for application in clinical and field epidemiological settings. *Acta Trop* 2003;85:253-261
4. Gharbi HA, Hassine W, Brauner MW, Dupuch K. Ultrasound examination of the hydatid liver. *Radiology* 1981;139:459-463.

5. Cai X, Cai H, Gan Q, et al. Case Report: Rare Presentation of Multivisceral Echinococcosis. *Am J Trop Med Hyg* 2019;100:1204-1207.
6. Imam A, Khoury T, Weis D, Khalayleh H, Adeleh M, Khalailah A. Laparoscopic cystectomy for pancreatic echinococcosis: A case report and literature review. *Ann Hepatobiliary Pancreat Surg* 2019;23:87-90.
7. Safioleas MC, Moulakakis KG, Manti C, Kostakis A. Clinical considerations of primary hydatid disease of the pancreas. *Pancreatol* 2005;5:457-461.
8. Dziri C, Haouet K, Fingerhut A. Treatment of hydatid cyst of the liver: where is the evidence? *World J Surg* 2004;28:731-736.
9. Soin P, Sharma P, Kochar PS. Pancreatic echinococcosis. *Proc (Bayl Univ Med Cent)* 2019;32:85-87.
10. Zalaquett E, Menias C, Garrido F, et al. Imaging of Hydatid Disease with a Focus on Extrahepatic Involvement. *Radiographics* 2017;37:901-923.
11. Rasheed K, Zargar SA, Telwani AA. Hydatid cyst of spleen: a diagnostic challenge. *N Am J Med Sci* 2013;5:10-20.
12. Culafig DM, Kerkez MD, Mijac DD, et al. Spleen cystic echinococcosis: clinical manifestations and treatment. *Scand J Gastroenterol* 2010;45:186-190.
13. Bhatnagar N, Kishan H, Sura S, Lingaiah P, Jaikumar K. Pelvic Hydatid Disease: A Case Report and Review of Literature. *J Orthop Case Rep* 2017;7:25-28.
14. Ran B, Shao Y, Yimiyi Y, et al. Spleen-preserving surgery is effective for the treatment of spleen cystic echinococcosis. *Int J Infect Dis* 2014;29:181-183.
15. Pandey S, Singh V, Sinha RJ, Sharma A. Pelvic hydatid: the great masquerader. *BMJ Case Rep* 2018;2018:bcr-2018-227409.
16. Kakaei F, Asvadi Kermani T, Tarvirdizade K. A case report: Primary hydatid cyst of uterus. *Int J Surg Case Rep* 2018;42:67-69.
17. Ertas IE, Gungorduk K, Ozdemir A, et al. Pelvic tuberculosis, echinococcosis, and actinomycosis: great imitators of ovarian cancer. *Aust N Z J Obstet Gynaecol* 2014;54:166-171.
18. Alonso Garcia ME, Suarez Mansilla P, Mora Cepeda P, Bayon Alvarez E, Alvarez Colomo C, Gonzalez Martin JJ. Ovarian hydatid disease. *Arch Gynecol Obstet* 2014;289:1047-1051.
19. Sarkar S, Sanyal P, Das MK, Kumar S, Panja S. Acute Urinary Retention due to Primary Pelvic Hydatid Cyst: A Rare Case Report and Literature Review. *J Clin Diagn Res* 2016;10:PD06-PD08.
20. Pedrosa I, Saiz A, Arrazola J, Ferreiros J, Pedrosa CS. Hydatid disease: radiologic and pathologic features and complications. *Radiographics* 2000;20:795-817.
21. Garg MK, Sharma M, Gulati A, et al. Imaging in pulmonary hydatid cysts. *World J Radiol* 2016;8:581-587.
22. El Fortia M, El Gatit A, Bendaoud M. Ultrasound wall-sign in pulmonary echinococcosis (new application). *Ultraschall Med* 2006;27:553-557.
23. Tana C, Schiavone C, Ticinesi A, et al. Ultrasound imaging of abdominal sarcoidosis: State of the art. *World J Clin Cases* 2019;7:809-818.
24. Yue Lee FC, Jenssen C, Dietrich CF. A common misunderstanding in lung ultrasound: the comet tail artefact. *Med Ultrason* 2018;20:379-384.
25. Dietrich CF, Mathis G, Blaivas M, et al. Lung artefacts and their use. *Med Ultrason* 2016;18:488-499.
26. Dietrich CF, Mathis G, Blaivas M, et al. Lung B-line artefacts and their use. *J Thorac Dis* 2016;8:1356-1365.
27. Dietrich CF, Mathis G, Cui XW, Ignee A, Hocke M, Hirche TO. Ultrasound of the pleurae and lungs. *Ultrasound Med Biol* 2015;41:351-365.
28. Santivanez S, Garcia HH. Pulmonary cystic echinococcosis. *Curr Opin Pulm Med* 2010;16:257-261.
29. Garcia MB, Lledias JP, Perez IG, et al. Primary super-infection of hydatid cyst--clinical setting and microbiology in 37 cases. *Am J Trop Med Hyg* 2010;82:376-378.
30. Arroud M, Afifi MA, El Ghazi K, Nejari C, Bouabdallah Y. Lung hydatid cysts in children: comparison study between giant and non-giant cysts. *Pediatr Surg Int* 2009;25:37-40.
31. Gogus C, Safak M, Baltaci S, Turkolmez K. Isolated renal hydatidosis: experience with 20 cases. *J Urol* 2003;169:186-189.
32. Ishimitsu DN, Saouaf R, Kallman C, Balzer BL. Best cases from the AFIP: renal hydatid disease. *Radiographics* 2010;30:334-337.
33. Turgut AT, Akhan O, Bhatt S, Dogra VS. Sonographic spectrum of hydatid disease. *Ultrasound Q* 2008;24:17-29.
34. Ignee A, Straub B, Brix D, Schuessler G, Ott M, Dietrich CF. The value of contrast enhanced ultrasound (CEUS) in the characterisation of patients with renal masses. *Clin Hemorheol Microcirc* 2010;46:275-290.
35. Kumar V, Misra V, Chaurasiya D, Verma N. Collecting duct carcinoma kidney masquerading as hydatid cyst: A rare case report and review of literature. *Indian J Pathol Microbiol* 2018;61:410-413.
36. Chemlali M, Sghaier S, Ghaleb M, Triki A, Ben Hassouna J, Rahal KB. A hydatid cyst of the appendix mimicking a uterine lateral mass: a case report. *J Med Case Rep* 2018;12:82.
37. Salamone G, Licari L, Randisi B, et al. Uncommon localizations of hydatid cyst. Review of the literature. *G Chir* 2016;37:180-185.
38. Banzo J, Diaz FJ, Pina JJ, et al. Multiple cerebral hydatid cysts. *Eur J Nucl Med* 1984;9:561-563.
39. Teke M, Gocmez C, Hamidi C, et al. Imaging features of cerebral and spinal cystic echinococcosis. *Radiol Med* 2015;120:458-465.
40. Svrckova P, Nabarro L, Chiodini PL, Jager HR. Disseminated cerebral hydatid disease (multiple intracranial echinococcosis). *Pract Neurol* 2019;19:156-163.
41. Thapa S, Ghosh A, Ghartimagar D, Shrestha S, Lalchan S, Talwar OP. Hydatidosis of infratemporal fossa with proptosis - an unusual presentation: a case report and review of the literature. *J Med Case Rep* 2018;12:309.
42. Lentzsch AM, Gobel H, Heindl LM. Primary Orbital Hydatid Cyst. *Ophthalmology* 2016;123:1410.
43. Pahwa S, Sharma S, Das CJ, Dhamija E, Agrawal S. Intraorbital Cystic Lesions: An Imaging Spectrum. *Curr Probl Diagn Radiol* 2015;44:437-448.