

Diagnostic accuracy of transvaginal ultrasound examination for local staging of cervical cancer: a systematic review and meta-analysis

Yu Tian, Hong Luo

Ultrasound Department, West China Second University Hospital, Sichuan University / Key Laboratory of Obstetrics and Gynecologic and Pediatric Diseases and Birth Defects of Ministry of Education, Chengdu, Si Chuan Province, China

Abstract

Aim: Transvaginal ultrasonography (TVUS) has shown varying results in the staging of cervical cancer patients around the world. Hence, the current review was done to assess the diagnostic accuracy of TVUS for identifying parametrial, stromal invasion and lymph node metastasis among cervical cancer patients. **Material and methods:** We conducted a systematic search for all studies reporting the diagnostic accuracy of TVUS for staging of cervical cancer in the databases of PubMed Central, MEDLINE, EMBASE, MEDLINE, SCOPUS and Cochrane library from inception till March 2021. Meta-analysis was performed using STATA software “midas” package. **Results:** Eleven studies with 760 patients were included. The pooled sensitivity and specificity of TVUS for diagnosing parametrial invasion were 62% (95% CI, 40-80) and 91% (95% CI, 79-97), for stromal invasion were 84% (95% CI, 77-90) and 80% (95% CI, 61-91), for lymph node metastasis were 52% (95% CI, 8-93) and 95% (95% CI, 68-99). There was significant heterogeneity found with all the outcomes with significant chi-square test and I^2 statistic >75%. **Conclusion:** TVUS has limited applicability and use as a screening or diagnostic tool for local staging of cervical cancer patients. Further reviews comparing multiple non-invasive imaging modalities are required to pick the best tool for local staging of cervical cancer.

Keywords: cancer staging; cervical cancer; meta-analysis; transvaginal ultrasonography

Introduction

Cervical cancer is one of the most common type of cancers among women worldwide [1]. It is also one of the leading causes of morbidity and mortality among females around the world [1]. Patients with cervical cancer were strictly staged based on the International Federation of Gynaecology & Obstetrics (FIGO) system by gynaecologic examination, and if required, colposcopy, cystoscopy, biopsy and proctoscopy were used until recently

[2]. This FIGO staging has been directly related to the prognosis of the patients and guides their stratification to various treatment regimens, which range from surgical resection to palliative chemotherapy or definitive chemoradiation [3]. However, the FIGO staging has underwent revision in the year 2018 [4]; since then, the available imaging techniques and pathological evaluations have been incorporated in the staging of cervical cancer.

Most of the health centres around the world have started using the imaging work-up for primary staging of cervical cancer patients [5]. For assessing the local tumour invasion, transvaginal ultrasound (TVUS) might provide an accurate and detailed information on the extent of local tumour, when performed by the ultrasound-trained gynaecologists [6,7]. The tissue of cervical cancer tissue has been depicted in TVUS as te hyperechoic or isoechoic lesions in the adenocarcinomas and as hypoechoic lesions in the squamous cell carcinomas [6,8]. TVUS performed at the experienced centres has reportedly yielded a comparable diagnostic staging metrics to a

Received 07.05.2021 Accepted 23.08.2021

Med Ultrason

2022, Vol. 24, No 3, 348-355

Corresponding author: Hong Luo

Ultrasound Department, West China Second University Hospital, Sichuan University / Key Laboratory of Obstetrics & Gynecologic and Pediatric Diseases and Birth Defects of Ministry of Education
Chengdu, Si Chuan Province, 610041, China
E-mail: wener17549@sina.com

pelvic magnetic resonance imaging (MRI) [6,9-11]. European multicentric trial has even reported that the TVUS can provide results more accurate than the MRI in the detection of parametrial invasion [12]. With the technical advances in the vaginal probes allowing increased depth penetration, TVUS may allow the visualization of the deeper pelvic structures to a certain extent.

In spite of all these advantages and technological advances, there has been no systematic evidence proving the diagnostic accuracy of TVUS using evidences around the world. In addition, there has been varying results produced by studies with regard to the accuracy of TVUS for staging of cervical cancer patients. Hence, this meta-analysis is being planned with the aim to evaluate the diagnostic accuracy of transvaginal ultrasound for local staging (stromal and parametrial invasion) and lymph node metastasis of cervical cancer.

Material and method

Study design

We have included the studies examining the diagnostic accuracy of TVUS for invasion of stroma or parametrium or lymph node metastasis, irrespective of the study design, only if they report sensitivity and specificity of the above-mentioned diagnostic technique or provide data to calculate these rates. These studies were conducted among patients with diagnosed cervical cancer irrespective of age, ethnicity or comorbidities and used TVUS for staging the cervical cancer. The studies were included only if the diagnostic accuracy of TVUS was compared with a standard laparoscopic or histopathological examination. Diagnosis using the reference standard had to be made by specialist doctors or trained researchers. The studies published with only abstract or unpublished data were excluded. Case reports and studies with smaller sample size (fixed at 10 for the current review) were also excluded.

As outcome measures, the pooled sensitivity, specificity, likelihood ratio positive (LRP), likelihood ratio negative (LRN) and diagnostic odds ratio (DOR) were calculated.

Search strategy

We conducted a comprehensive, systematic and extensive search in the electronic databases such as PubMed Central, MEDLINE, EMBASE, MEDLINE, SCOPUS and Cochrane library. The terms required for the search were selected during the protocol stage itself. We used both medical subject headings (MeSH) and free-text words to search all these databases. The set of keywords and their synonyms was used for search using appropriate truncations, wildcards and proximity searching. The

following MeSH terms and free text terms were used in PubMed search engine in various combinations: “Validation Studies”, “Cervical Neoplasm”, “Cervical Cancer”, “Transvaginal Ultrasonography”, “Stromal Invasion”, “Malignant Cervical Lesion”, “Gynaecological Disorders”, “Sensitivity”, “Specificity”, “Diagnosis”, “Parametrial Invasion”, “Lymph node Metastasis” and “Diagnostic Accuracy Studies”. Similar terms will be used in Cochrane library, Scopus and Embase for literature search of published studies. Search also was conducted for key concepts using corresponding subject headings in each database. The final search was carried out by combining the individual search results using appropriate Boolean operators (“OR” and “AND”). We restricted the search from the inception of the databases to March 2021 and published in English language only. Bibliographies of the retrieved articles are also hand-searched to identify any articles missed during the database search.

Selection of studies

Two independent investigators (YT and HL) have performed primary screening of title, abstract and keywords by executing the literature search. All the citations along with the title and abstract was imported to a specified endnote library and a final list of studies to be screened for inclusion in the study was prepared by removing the duplicates. Full-text articles were retrieved for these shortlisted studies. Full-text of these obtained articles were screened by the same two investigators (YT and HL) and assessed against the eligibility criteria of our review. Studies not satisfying the eligibility criteria were excluded and reasons for exclusion were noted. Any disagreements between the two investigators during the screening process was resolved and a final selection of studies was done in consensus between the two investigators (YT and HL). “PRISMA flow chart” was used to clearly represent the screening and selection process [13].

Data extraction and management

Primary author (YT) has extracted the relevant study characteristics for the review from the included studies. The following data were extracted: study design, study setting, index test, reference standards (gold standard/comparator), and stage of cervical cancer, total number of participants, average age, inclusion, exclusion criteria, test positives (true & false) and negatives (true & false). Data was transferred into STATA software. Data quality was assured by the second investigator (HL) who performed the double checking of the entered data with original study reports.

Risk of bias assessment

Two independent authors (YT and HL) evaluated the bias risk using the “Quality Assessment of Diagnostic

Accuracy Studies-2 (QUADAS-2) tool” [14]. The following domains were used for assessing the risk of bias: selection of patients, index tests, reference standards, flow and timing of assessments. Grading was done as high, low and unclear for the source of bias among all included studies.

Statistical analysis

Meta-analysis was done using STATA 14.2 (“Stata-Corp, College Station, TX, USA”) to get the pooled values of sensitivity, specificity, LRP, LRN and summary DOR for TVUS. “Summary Receiver Operator Characteristic curves (sROC)” was constructed. Study spe-

cific and pooled estimates were graphically represented through a forest plot. A Fagan plot was constructed to demonstrate how much the result on TVUS changes the probability that a patient has parametrial or stromal invasion or lymph node metastasis. LR scattergram was used to determine the clinical value of TVUS. Evidence of between-study variance due to heterogeneity was assessed through three methods: graphical representation through bivariate box plot, chi square test for heterogeneity and I² statistics to quantify the inconsistency. I² less than 25% is mild, 25-75% is moderate and more than 75% is considered as substantial heterogeneity.

Results

Study selection

We found 1,126 records through the systematic literature search and deemed 120 of those studies relevant for full-text retrieval. We also retrieved full texts for six articles obtained through manual searching of the bibliographies in the retrieved studies. During the second screening stage, 11 studies with 760 participants met the inclusion criteria and were used in our analysis (fig 1) [12,15-24].

Characteristics of included studies

Table I shows the characteristics of included studies. All the included studies were prospective. Majority of the included studies were conducted in European countries such as Italy, Ireland, Poland, Sweden etc., followed by Asian countries such as India, China and Korea. The mean age of the study participants ranged from 40 to 56 years. We analysed data from 760 patients to assess the diagnostic accuracy of TVUS (the samples sizes ranged from 24 to 182 patients). Majority of the included studies (8 out of 11 studies) [12,15-18,20,22,23] have assessed the accuracy of TVUS for parametrial invasion followed by stromal invasion (4 studies) [12,20,21,23] and lymph node metastasis (4 studies) [19,21,23,24]. All the studies used histopathology/biopsy as the reference standard.

Risk of bias assessment

Figure 2 shows the risk of bias across various domains as per the QUADAS tool results. We found that none of the studies had a high patient selection bias risk, 3 studies had a high conduct and interpretation of index test bias risk [12,19,20], 3 studies had a high patient flow and interval between index tests and reference standards bias risk [18,21,24] and 1 study had a high reference standards bias risk [17].

Diagnostic accuracy of TVUS

The utility of TVUS for diagnosing parametrial invasion was reported in 8 studies [12,15-18,20,22,23]. The pooled sensitivity and specificity of TVUS for diagnos-

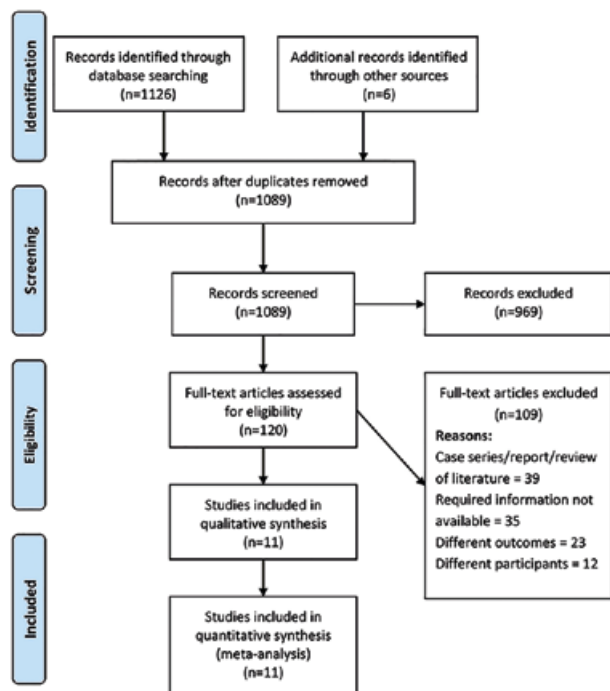


Fig 1. Search strategy.

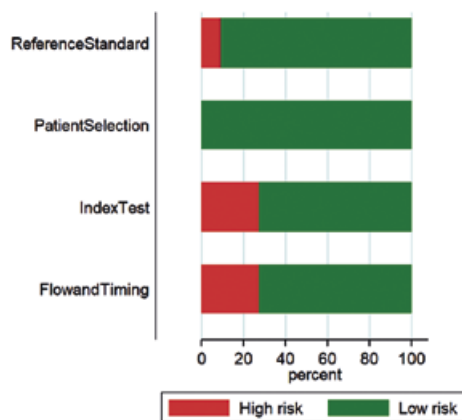


Fig 2. Quality assessment among the included studies using QUADAS-2 tool (n=11).

Table I. Characteristics of the included studies (N=11)

| S.No | First author and year | Country | Sample size | Study participants (Cervical cancer stage) | Reference standard | Mean age (years) | Outcomes assessed | Quality of study |
|------|-----------------------|--|-------------|---|--------------------|------------------|---|------------------|
| 1 | Byun 2013 [15] | Korea | 24 | Patients with locally invasive cervical cancer | Histopathology | 49.3 | Parametrial invasion | High |
| 2 | Cendrowski 2003 [16] | Poland | 101 | Patients with stage IB cervical cancer | Histopathology | 56 | Parametrial invasion | High |
| 3 | Epstei 2013 [12] | Multi-center (Sweden, Italy, Lithuania, Czech) | 182 | Patients with IA2 to IIA1 cervical cancer | Histopathology | 46.3 | Parametrial and stromal invasion | High |
| 4 | Ghi 2007 [17] | Italy | 28 | Invasive cervical cancer patients | Histopathology | 52 | Parametrial invasion | Low |
| 5 | Ma 2017 [18] | China | 39 | Patients with Stage IB1 to IV cervical cancer | Histopathology | 52.4 | Parametrial invasion | High |
| 6 | Mamsen 1995 [19] | Denmark | 111 | Patients with Stage IB to IIA cervical cancer | Histopathology | 45 | Lymph node metastasis | High |
| 7 | Moloney 2016 [20] | Ireland | 33 | Patients with Stage IB to IV cervical cancer | Histopathology | 44 | Parametrial and stromal invasion | High |
| 8 | Pálsdóttir 2015 [21] | Multi-center (Sweden, Italy, Czech) | 104 | Patients with Stage IA to IIB cervical cancer | Histopathology | Not reported | Stromal invasion and lymph node metastasis | High |
| 9 | Perniola 2020 [22] | Italy | 38 | Patients with Stage IA to IV cervical cancer | Histopathology | 55.3 | Parametrial invasion | High |
| 10 | Test 2009 [23] | Italy | 68 | Patients with Stage IB2 to IIIB cervical cancer | Histopathology | 51 | Parametrial and stromal invasion, lymph node metastasis | High |
| 11 | Xiu-wei 2013 [24] | China | 32 | Cervical cancer patients (staging not reported) | Histopathology | Not reported | Lymph node metastasis | High |

ing parametrial invasion were 62% (95% CI, 40-80) and 91% (95% CI, 79-97), respectively (fig 3, fig 4). The area under the sROC curve was 0.80 (95%CI: 0.75-0.85). The DOR was 17 (95% CI, 3-82). LRP was 7 (95% CI, 2-21) and LRN was 0.42 (0.23-0.75). The LR scattergram (fig 5) shows that the LRP and LRN are in the right lower quadrant. Figure 6 shows a high clinical utility of TVUS for diagnosing parametrial invasion (positive=54%; neg-

ative=6%) differing significantly from the pre-test probability (14%). We also found significant between-study variability (heterogeneity) with a chi-square p value <0.001 and an $I^2 > 75%$. The bivariate box plot further confirmed the heterogeneity (fig 7). However, we could not perform meta-regression to find the heterogeneity due to the limited number of included studies. Publication bias also cannot be checked due to similar reasons.

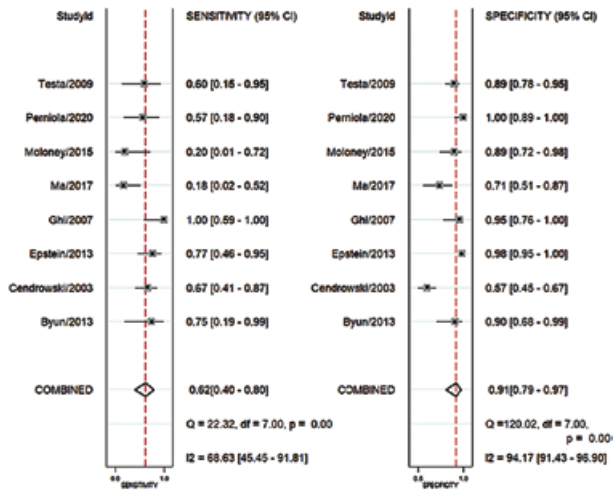


Fig 3. Forest plot showing pooled sensitivity and specificity of TVUS for parametrial invasion

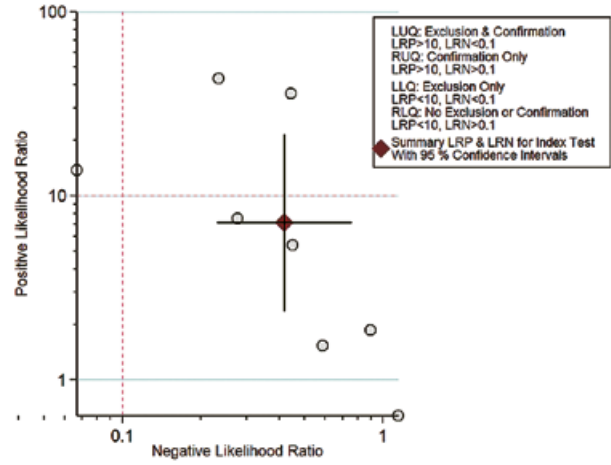


Fig 5. Likelihood scatter gram for TVUS for parametrial invasion

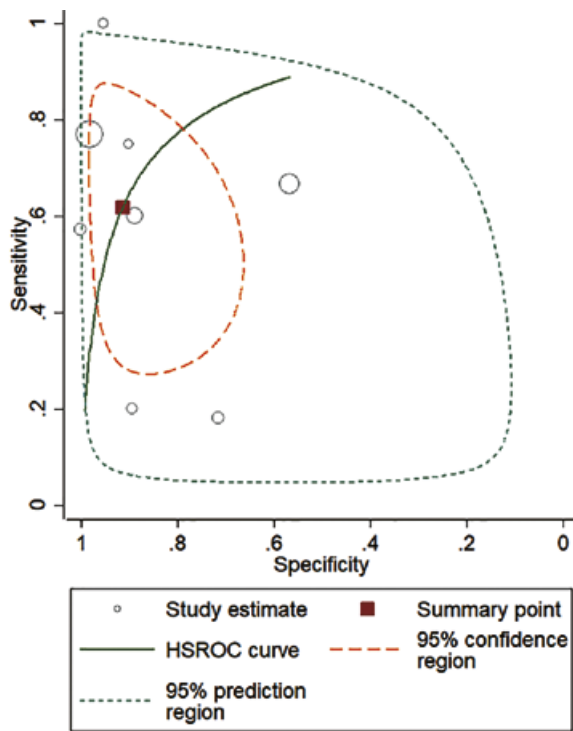


Fig 4. SROC Curve for TVUS in diagnosing the parametrial invasion

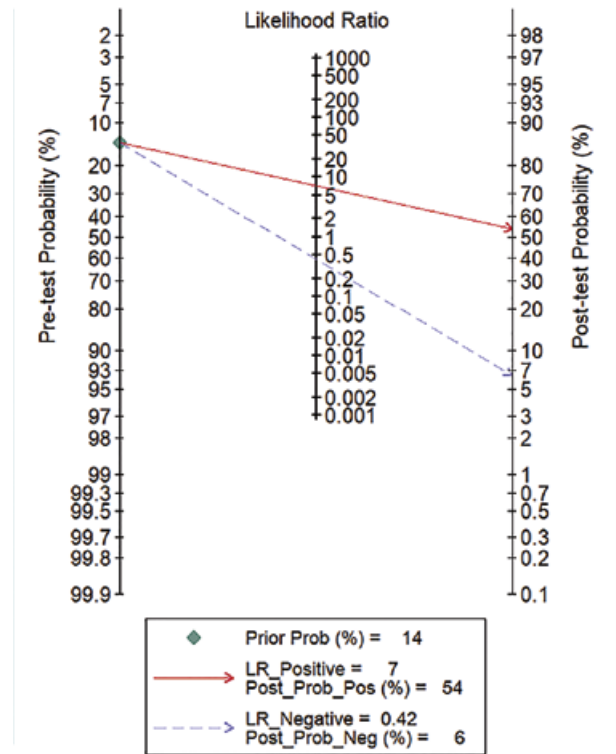


Fig 6. Fagan nomogram evaluating the overall value of TVUS for parametrial invasion

The utility of TVUS for diagnosing stromal invasion was reported in 4 studies [12,20,21,23]. The pooled sensitivity and specificity of TVUS for diagnosing stromal invasion were 84% (95% CI, 77-90) and 80% (95% CI, 61-91), respectively. We found significant between-study variability (heterogeneity) with a chi-square p value <0.001 and an $I^2 > 75%$ for stromal invasion also. The accuracy of TVUS for lymph node metastasis was also reported in 4 studies [19,21,23,24]. The pooled sensitivity and specificity of TVUS for diagnosing lymph node metastasis were 52% (95% CI, 8-93) and 95% (95% CI, 68-99), respectively. Significant between-study variability (heterogeneity) was found with this outcome also with a chi-square p value <0.001 and an $I^2 > 75%$. Other accuracy parameters could not be assessed due to the limited number of studies in both these outcomes.

Discussion

We have assessed the accuracy of TVUS for diagnosing parametrial, stromal infiltration and lymph node metastasis among cervical cancer patients with histopathological findings as the reference standard. After the systematic literature search, we found 11 studies (all prospective in nature and with low bias risks) reporting the accuracy of TVUS for staging the cervical cancer patients. We found that TVUS had better sensitivity (84%) and specificity (80%) for identifying stromal infiltration followed by parametrial infiltration. TVUS had the highest specificity (95%) for the identification of lymph node metastasis, while the sensitivity (52%) was the least for the same outcome. Other accuracy parameters could be assessed for only parametrial invasion. TVUS showed a moderate diagnostic accuracy for the identification of parametrial invasion: in the LR scattergram, LRN and LRP occupied the right lower quadrant indicating that the imaging technique cannot be used for confirmation and exclusion. The clinical utility of TVUS was also significantly better as the Fagan's nomogram showed a significant rise in the post-TVUS probability compared to the pre-TVUS probability.

The accuracy parameters for the TVUS we obtained in this review are similar to those reported by the previous evidence [25,26]. However, the accuracy of TVUS was lesser than other imaging technique like diffusion weighted magnetic resonance imaging (DW-MRI), positron emission tomography/Computed tomography (PET/CT), CT or MRI. This shows that TVUS has limited applicability in the staging of cervical cancer compared to other non-invasive modalities [26,27]. However, further updated reviews should compare the diagnostic performance of TVUS with other similar diagnostic techniques

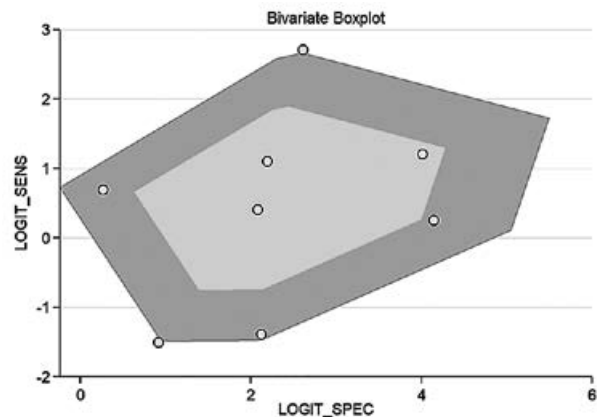


Fig 7. Bivariate boxplot of the sensitivity and specificity in the included studies

to capture the best technique for screening of cervical cancer patients. In addition, large-scale longitudinal studies are required to check the diagnostic accuracy of TVUS based on the different stage of cervical cancer (early or advanced stage).

However, our results should be interpreted with caution and inferred accordingly, considering the difference in methods and quality across the included studies. In our analysis, we found significant between-study variability (significant chi-square test for heterogeneity and I^2 statistics).

Our review has certain strengths. This is the first meta-analysis assessing the accuracy of TVUS for the staging of cervical cancer in terms of parametrial, stromal invasion and lymph node metastasis. Another strength of the study is the inclusion of only prospective studies, making the study finding more reliable. Majority of the included studies had low risk of bias, adding to the credibility of the evidence.

However, we are also aware of the limitations in our review. First of all, we found a significant heterogeneity (between-study variability) in our analysis. We could not assess the source of heterogeneity for any of the outcomes due to the limited number of studies included in our review. This limits the ability to interpret or infer the obtained pooled results. Second, the diagnostic accuracy of the TVUS depends on various factors such as the ethnicity of the participants, timing of the TVUS assessment, and severity and risk factors of the patients. However, we could not assess the influence of any of these factors. Third, we could not assess the publication bias due to limited number of studies in the review.

Despite these shortcomings, our findings provide valuable information and important implications for the clinical management of cervical cancer and suggest that TVUS has only a moderate accuracy parameter for stag-

ing these patients. Though, the use of TVUS can help the patients to have a significant reduction in the time spent during the diagnostic procedures and also causes reduction in the healthcare costs involved, the level of accuracy limits its usage among the patients. Hence, there is a need to identify other non-invasive modality with better sensitivity and specificity to act as an effective screening and diagnostic tool. This is important because early staging of the cervical cancer patients can further lead to more effective therapeutic management of the diagnosed patients. Large-scale setting-specific longitudinal studies are required to establish the best non-invasive modality as the standard assessment tool for all the patients diagnosed with cervical cancer.

Conflict of interest: none

References

1. Cancer Today - International Agency for Research on Cancer. Cancer Fact Sheets. Available at: <https://gco.iarc.fr/today/fact-sheets-cancers>. Accessed 20 April 2021.
2. Pecorelli S. Revised FIGO staging for carcinoma of the vulva, cervix, and endometrium. *Int J Gynaecol Obstet* 2009;105:103–104.
3. Pfaendler KS, Tewari KS. Changing paradigms in the systemic treatment of advanced cervical cancer. *Am J Obstet Gynecol* 2016;214:22–30.
4. Bhatla N, Berek JS, Cuello Fredes M, et al. Revised FIGO staging for carcinoma of the cervix uteri. *Int J Gynaecol Obstet* 2019;145:129–135.
5. Haldorsen IS, Lura N, Blaakær J, Fischerova D, Werner HMJ. What Is the Role of Imaging at Primary Diagnostic Work-Up in Uterine Cervical Cancer? *Curr Oncol Rep* 2019;21:77.
6. Testa AC, Di Legge A, De Blasis I, et al. Imaging techniques for the evaluation of cervical cancer. *Best Pract Res Clin Obstet Gynaecol* 2014;28:741–768.
7. Cibula D, Potter R, Planchamp F, et al. The European Society of Gynaecological Oncology/European Society for Radiotherapy and Oncology/ European Society of Pathology Guidelines for the management of patients with cervical cancer. *Int J Gynecol Cancer* 2018;28:641–655.
8. Epstein E, Di Legge A, Masback A, Lindqvist PG, Kanisto P, Testa AC. Sonographic characteristics of squamous cell cancer and adenocarcinoma of the uterine cervix. *Ultrasound Obstet Gynecol* 2010;36:512–516.
9. Bipat S, Glas AS, van der Velden J, Zwinderman AH, Bossuyt PM, Stoker J. Computed tomography and magnetic resonance imaging in staging of uterine cervical carcinoma: a systematic review. *Gynecol Oncol* 2003;91:59–66.
10. Selman TJ, Mann C, Zamora J, Appleyard TL, Khan K. Diagnostic accuracy of tests for lymph node status in primary cervical cancer: a systematic review and meta-analysis. *CMAJ* 2008;178:855–862.
11. Hricak H, Gatsonis C, Coakley FV, et al. Early invasive cervical cancer: CT and MR imaging in preoperative evaluation - ACRIN/GOG comparative study of diagnostic performance and interobserver variability. *Radiology* 2007;245:491–498.
12. Epstein E, Testa A, Gaurilcikis A, et al. Early-stage cervical cancer: tumor delineation by magnetic resonance imaging and ultrasound - a European multicenter trial. *Gynecol Oncol* 2013;128:449–453.
13. Moher D, Altman DG, Liberati A, Tetzlaff J. PRISMA statement. *Epidemiology* 2011;22:128.
14. Whiting PF, Rutjes AW, Westwood ME, et al. QUADAS-2: a revised tool for the quality assessment of diagnostic accuracy studies. *Ann Int Med* 2011;155:529–536.
15. Byun JM, Kim YN, Jeong DH, Kim KT, Sung MS, Lee KB. Three-Dimensional Transvaginal Ultrasonography for Locally Advanced Cervical Cancer. *Int J Gynecol Cancer* 2013;23:1459–1464.
16. Cendrowski K, Sawicki W, Spiewankiewicz B, Stelmachów J. The importance of fine needle aspiration biopsy and sonographic evaluation of parametria in cervical cancer. *Eur J Gynaecol Oncol* 2003;24:413–416.
17. Ghi T, Giunchi S, Kuleva M, et al. Three-dimensional transvaginal sonography in local staging of cervical carcinoma: description of a novel technique and preliminary results. *Ultrasound Obstet Gynecol* 2007;30:778–782.
18. Ma X, Li Q, Wang JL, et al. Comparison of elastography based on transvaginal ultrasound and MRI in assessing parametrial invasion of cervical cancer. *Clin Hemorheol Microcirc* 2017;66:27–35.
19. Mamsen A, Ledertoug S, Hørlyck A, et al. The possible role of ultrasound in early cervical cancer. *Gynecol Oncol* 1995;56:187–190.
20. Moloney F, Ryan D, Twomey M, Hewitt M, Barry J. Comparison of MRI and high-resolution transvaginal sonography for the local staging of cervical cancer: TVS for Staging Cervical Cancer. *J Clin Ultrasound* 2016;44:78–84.
21. Pálsdóttir K, Fischerova D, Franchi D, Testa A, Di Legge A, Epstein E. Preoperative prediction of lymph node metastasis and deep stromal invasion in women with invasive cervical cancer: prospective multicenter study using 2D and 3D ultrasound. *Ultrasound Obstet Gynecol* 2015;45:470–475.
22. Perniola G, Fischetti M, Tomao F, et al. Evaluation of Parametrial Status in Locally Advanced Cervical Cancer Patients after Neoadjuvant Chemotherapy: A Prospective Study on Diagnostic Accuracy of Three-Dimensional Transvaginal Ultrasound. *Oncology* 2020;98:603–611.
23. Testa AC, Ludovisi M, Manfredi R, et al. Transvaginal ultrasonography and magnetic resonance imaging for assessment of presence, size and extent of invasive cervical cancer. *Ultrasound Obstet Gynecol* 2009;34:335–344.
24. Xue XW, Zhao ZH, Tian X, et al. The diagnostic value of transvaginal ultrasound in lymph node metastasis of cer-

- vical cancer patients. *Chinese J Clin Oncol Rehab* 2013; 2:161-162.
25. Haldorsen IS, Lura N, Blaakær J, Fischerova D, Werner HMJ. What Is the Role of Imaging at Primary Diagnostic Work-Up in Uterine Cervical Cancer? *Curr Oncol Rep* 2019;21:77.
26. Alcazar JL, García E, Machuca M, et al. Magnetic resonance imaging and ultrasound for assessing parametrial infiltration in cervical cancer. A systematic review and meta-analysis. *Med Ultrason* 2020;22:85-91.
27. Liu B, Gao S, Li S. A Comprehensive Comparison of CT, MRI, Positron Emission Tomography or Positron Emission Tomography/CT, and Diffusion Weighted Imaging-MRI for Detecting the Lymph Nodes Metastases in Patients with Cervical Cancer: A Meta-Analysis Based on 67 Studies. *Gynecol Obstet Invest* 2017;82:209-222.