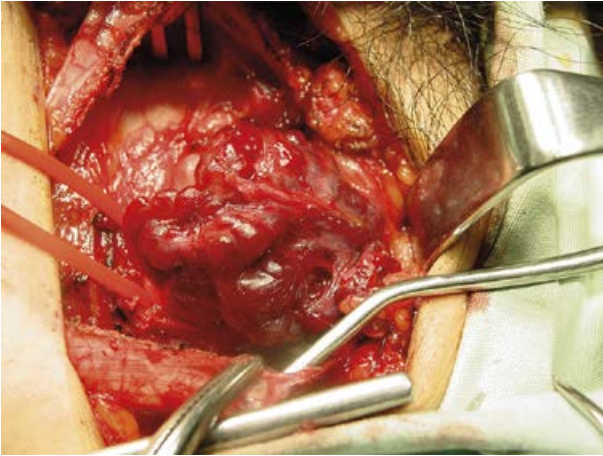


**Supplementary figure**



**Supplemental figure** Intraoperative finding showing reddish enlarged varicosities when the anterior wall of the inguinal canal was opened.